

ORIGINAL ARTICLE

Correspondence:

George A. Kanakis, Unit of Reproductive Endocrinology, First Department of Obstetrics and Gynecology, Aristotle University of Thessaloniki, Thessaloniki, Greece.
E-mail: geokan@endo.gr

*Shared first authors

**Shared last authors

Keywords:

diagnosis, gynecomastia, male breast cancer, management, testosterone

Received: 31-Mar-2019

Accepted: 1-Apr-2019

doi: 10.1111/andr.12636

EAA clinical practice guidelines—gynecomastia evaluation and management

^{1,*}G. A. Kanakis , ^{2,*}L. Nordkap , ²A. K. Bang, ³A. E. Calogero ,
⁴G. Bártfai, ⁵G. Corona, ⁶G. Forti, ⁷J. Toppari, ^{1,**}D. G. Goulis
and ^{2,**}N. Jørgensen 

¹First Department of Obstetrics and Gynecology, Unit of Reproductive Endocrinology, Aristotle University of Thessaloniki, Thessaloniki, Greece, ²University Department of Growth and Reproduction, and International Center for Research and Research Training in Endocrine Disruption of Male Reproduction and Child Health (EDMaRC), Rigshospitalet, Copenhagen, Denmark, ³Department of Clinical and Experimental Medicine, University of Catania, Catania, Italy, ⁴Department of Obstetrics, Gynecology, and Andrology, Albert Szent-Györgyi Medical University, Szeged, Hungary, ⁵Medical Department, Endocrinology Unit, Azienda Usl, Maggiore-Bellaria Hospital, Bologna, Italy, ⁶Department of Experimental Clinical and Biomedical Sciences 'Mario Sero', Endocrine Unit, University of Florence, Florence, Italy, and ⁷Institute of Biomedicine, Research Centre for Integrative Physiology and Pharmacology, Turku University Hospital, Turku, Finland

ABSTRACT

Background: Gynecomastia (GM) is a benign proliferation of the glandular tissue of the breast in men. It is a frequent condition with a reported prevalence of 32–65%, depending on the age and the criteria used for definition. GM of infancy and puberty are common, benign conditions resolving spontaneously in the majority of cases. GM of adulthood is more prevalent among the elderly and proper investigation may reveal an underlying pathology in 45–50% of cases.

Objectives: The aim was to provide clinical practice guidelines for the evaluation and management of GM.

Materials and methods: A literature search of articles in English for the term 'gynecomastia' was conducted. Evidence-based recommendations were developed using the Grading of Recommendations, Assessment, Development, and Evaluation (GRADE) system.

Results: A set of five statements and fifteen clinical recommendations was formulated.

Conclusions: The purpose of GM assessment should be the detection of underlying pathological conditions, reversible causes (administration/abuse of aggravating substances), and the discrimination from other breast lumps, particularly breast cancer. Assessment should comprise a thorough medical history and physical examination of the breast and genitalia (including testicular ultrasound). A set of laboratory investigations may integrate the evaluation: testosterone (T), estradiol (E2), sex hormone-binding globulin (SHBG), luteinizing hormone (LH), follicular stimulating hormone (FSH), thyroid stimulating hormone (TSH), prolactin, human chorionic gonadotropin (hCG), alpha-fetal protein (AFP), liver and renal function tests. Breast imaging may be used whenever the clinical examination is equivocal. In suspicious lesions, core needle biopsy should be sought directly instead. Watchful waiting is recommended after treatment of underlying pathology or discontinuation of substances associated with GM. T treatment should be offered to men with proven T deficiency. The use of selective estrogen receptor modulators (SERMs), aromatase inhibitors (AIs) and non-aromatizable androgens is not justified in general. Surgical treatment is the therapy of choice for patients with long-lasting GM.

SUMMARY OF STATEMENTS (S) AND RECOMMENDATIONS (R)

- S1.** Gynecomastia (GM) is a benign proliferation of glandular tissue of the breast in males.
- S2.** GM of infancy is a common condition that usually resolves spontaneously, typically within the first year of life.
- S3.** GM of puberty is a common condition, affecting approximately 50% of mid-pubertal boys; in more than 90% of cases, it resolves spontaneously within 24 months.

- S4.** The prevalence of GM in adulthood increases with increasing age; proper investigation may reveal an underlying pathology in approximately 45–50% of the cases.

- S5.** Male breast cancer is rare; GM should not be considered a premalignant condition.

The following recommendations are divided into 'strong', denoted by the number 1 and associated with the terminology

'we recommend', and 'weak' denoted by the number 2 and associated with the phrase 'we suggest'. The grading of the quality of evidence is denoted as follows: ⊕○○○ for very low-quality evidence; ⊕⊕○○ for low quality; ⊕⊕⊕○ for moderate quality; and ⊕⊕⊕⊕ for high quality.

- R1.** The presence of an underlying pathology should be considered in GM of adulthood. We recommend that the identification of an apparent reason for GM in adulthood, including the use of medication known to be associated with GM, should not preclude a detailed investigation (1 ⊕⊕⊕○).
- R2.** We suggest that the initial screening to rule out lipomastia, obvious breast cancer, or testicular cancer might be performed by a general practitioner or another non-specialist (2 ⊕○○○).
- R3.** We recommend that in those cases where a thorough diagnostic workup is warranted, it should be performed by a specialist (1 ⊕○○○).
- R4.** We recommend that the medical history should include information on the onset and duration of GM, sexual development and function, and administration or abuse of substances associated with GM (1 ⊕⊕⊕○).
- R5.** We recommend that the physical examination should detect signs of under-virilization or systemic disease (1 ⊕⊕⊕⊕).
- R6.** We recommend that breast examination should confirm the presence of palpable glandular tissue to discriminate GM from lipomastia (pseudo-gynecomastia) and rule out the suspicion of malignant breast tumor (1 ⊕⊕⊕⊕).

- R7.** We recommend that the physical examination should include the examination of the genitalia to rule out the presence of a palpable testicular tumor and to detect testicular atrophy (1 ⊕⊕⊕⊕).
- R8.** We recommend that genitalia examination is aided by a testicular ultrasound, as the detection of a testicular tumor by palpation has low sensitivity (1 ⊕⊕○○).
- R9.** We suggest that a set of evaluations may include T, E₂, SHBG, LH, FSH, TSH, prolactin, hCG, AFP, and liver and renal function tests (2 ⊕⊕○○).
- R10.** We suggest that breast imaging may offer assistance, where the clinical examination is equivocal (2 ⊕⊕○○).
- R11.** We suggest that, if the clinical picture is suspicious for a malignant lesion, core needle biopsy should be performed (2 ⊕⊕○○).
- R12.** We recommend watchful waiting after treatment of underlying pathology or discontinuation of the administration/abuse of substances associated with GM (1 ⊕⊕⊕○).
- R13.** We recommend that T treatment should be offered only to men with proven testosterone deficiency (1 ⊕⊕⊕○).
- R14.** We do not recommend the use of selective estrogen receptor modulators (SERMs), aromatase inhibitors (AIs), or non-aromatizable androgens in the treatment of GM in general (1 ⊕⊕○○).
- R15.** We suggest surgical treatment only for patients with long-lasting GM, which does not regress spontaneously or following medical therapy. The extent and type of surgery depend on the size of breast enlargement, and the amount of adipose tissue (2 ⊕⊕○○).

INTRODUCTION—DEFINITION

Gynecomastia (GM) is a benign proliferation of glandular tissue of the breast in men. The term is derived from the Greek words 'gynēka' (woman) and 'mastōs' (breast). GM can be unilateral or bilateral, most commonly the latter (Nuttall, 1979; Mieritz *et al.*, 2017). GM has to be distinguished from pseudo-gynecomastia (i.e., lipomastia), which is characterized by excess fat deposition without glandular proliferation.

GM is a common condition with a prevalence that varies widely between 32 and 65%, depending on the age of the subjects studied and the criteria used for GM definition (Braunstein, 2007). GM shows three discrete peaks throughout a man's lifespan: the first peak is observed during infancy, the second during puberty, and the third in middle-aged and elderly men (Nachtigall, 1965; Knorr & Bidlingmaier, 1975; Nuttall, 1979). The purpose of the assessment of GM should be the detection of underlying pathological conditions and the discrimination from other breast lumps that mimic GM, particularly breast cancer.

In this guideline, we provide recommendations regarding the evaluation and management of GM based on the GRADE (Grading of Recommendations, Assessment, Development, and Evaluation) system for grading both the quality of evidence and the strength of recommendations (Swiglo *et al.*, 2008). According to this system, the strength of recommendation is divided into 'strong', denoted by the number 1 and associated with the terminology 'we recommend', and 'weak' denoted by the number 2 and associated with the phrase 'we suggest'. The grading of the

quality of evidence is denoted as follows: ⊕○○○ for very low-quality evidence; ⊕⊕○○ for low quality; ⊕⊕⊕○ for moderate quality; and ⊕⊕⊕⊕ for high quality (Swiglo *et al.*, 2008).

EPIDEMIOLOGY

Statements

- S1.** Gynecomastia (GM) is a benign proliferation of glandular tissue of the breast in males.
- S2.** GM of infancy is a common condition that usually resolves spontaneously, typically within the first year of life.
- S3.** GM of puberty is a common condition, affecting approximately 50% of mid-pubertal boys; in more than 90% of cases, it resolves spontaneously within 24 months.
- S4.** Prevalence of GM in adulthood increases with increasing age; proper investigation may reveal an underlying pathology in approximately 45–50% of the cases.
- S6.** Male breast cancer is rare; GM should not be considered a premalignant condition.

Evidence

Newborns and infants

GM develops in 65–90% of all newborns as a possible consequence of the persistent action of estrogens, progesterone, and mammatropic peptides that characterize the intrauterine milieu. It usually resolves spontaneously a few weeks after birth,

coinciding with the withdrawal of maternal hormones from the neonate's circulation (Nachtigall, 1965). However, GM of the newborns may persist or even reappear in the first months of infancy, during the so-called 'mini-puberty' period, when a transient activation of the hypothalamic–pituitary–gonadal (HPG) axis occurs, causing an imbalance between estrogen and androgen concentrations (McKiernan & Hull, 1981; Madlon-Kay, 1986; Jayasinghe *et al.*, 2010). GM of infancy is not associated with any sequels or aberrations of development; typically, it does not persist after the first year of life (Schmidt, 2002).

Adolescents

The prevalence of GM in adolescents varies from 22 to 69% (Nydick *et al.*, 1961; Moore *et al.*, 1984; Biro *et al.*, 1990). The peak prevalence is observed during mid-puberty (Kumanov *et al.*, 2007; Kilic *et al.*, 2011; Mieritz *et al.*, 2015), when the sex hormones surge, and growth and pubertal development are at the highest rate since the neonatal period (Tinggaard *et al.*, 2012). Some pubertal boys experience intermittent GM (Mieritz *et al.*, 2015). Underlying endocrinopathy cannot be detected in the vast majority of cases, and it has been stated that spontaneous regression can be expected within 6 months or less (Biro *et al.*, 1990; Braunstein, 2007), but may persist up to 1–2 years (Lee *et al.*, 1990; Nydick *et al.*, 1961). The latter is in agreement with a recent longitudinal study, where the median duration of pubertal GM was 1.9 years (Mieritz *et al.*, 2015) (Fig. 1) and thus longer than previously stated. In a cross-sectional study of 19-year-old Danish men from the general population, 2.8% were found to have persistent pubertal GM (Priskorn *et al.*, 2018). Other studies have reported a frequency of 10%, however, in more selected populations (Nydick *et al.*, 1961; Akgül *et al.*, 2014; Mieritz *et al.*, 2017).

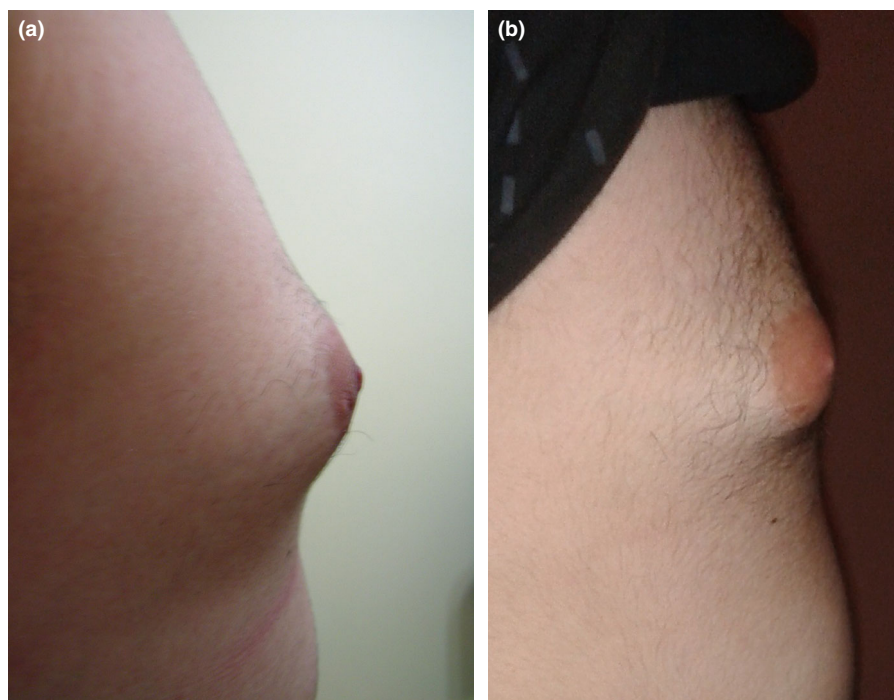
Adults

The reported prevalence of GM in adult men varies widely, partly because of different diagnostic criteria applied and partly because of selection of study populations; it has been stated to be as high as 36–57%, especially among the elderly (Nuttall, 1979; Niewoehner & Nuttall, 1984; Georgiadis *et al.*, 1994). The corresponding figure at autopsy series is 40–55% (Williams, 1963). Although these figures may seem higher than clinical experience may suggest, there is no doubt that GM incidence and prevalence in elderly men are high. An underlying pathology may be found in approximately 45–50% of adult men with GM. The most prevalent causes are systemic diseases, medical treatment, obesity, and endocrinopathies, including testosterone (T) deficiency (Nuttall, 1979; Niewoehner & Nuttall, 1984; Georgiadis *et al.*, 1994; Mieritz *et al.*, 2017). Depending on the size and duration, GM may regress to some degree, if treatment of the underlying causes is feasible. If persistence exceeds one year, development of fibrosis and hyalinization is likely to occur (Braunstein, 2007), making spontaneous regression less likely even if the causative factor is removed (Nicolis *et al.*, 1971; Bannayan & Hajdu, 1972).

Breast cancer

Male breast cancer is rare (lifetime risk of 0.1%) (Yu *et al.*, 2015). Risk factors for breast cancer in men are Klinefelter syndrome (Brinton, 2011), a history of chest irradiation, and a family history of breast cancer (particularly mutations of the BRCA2 gene) (Biesma *et al.*, 2015; Laitman *et al.*, 2015). GM does not increase the risk of breast cancer (Volpe *et al.*, 1999; Fentiman *et al.*, 2006; Yu *et al.*, 2015).

Figure 1 Gynecomastia of puberty: (A) at the age of 14 years and (B) at the age of 15.5 years. Spontaneous regression of breast enlargement is observed with associated progression of virilization (courtesy of Dr. G. Kanakis).



Values and preferences

Our statements stress the fact that GM is a common finding in infancy and puberty as a result of normal maturing processes and reflect our preference to avoid unnecessary testing of otherwise healthy boys. On the other hand, it is stated that GM of adulthood is associated with an underlying pathology in 50% of cases, warranting further evaluation.

PATHOPHYSIOLOGY

The exact mechanisms that lead to the development of GM are not entirely elucidated, but an increase in the estrogen-to-androgen balance is suggested to play an important role (Mathur & Braunstein, 1997; Narula & Carlson, 2014). Breast tissue contains receptors for both estrogens and androgens (Nichols *et al.*, 1987; Sasano *et al.*, 1996; Kanhai *et al.*, 2000) (Fig. 2 adapted from Narula & Carlson, 2014). Estrogens stimulate proliferation, whereas androgens inhibit growth and differentiation of the mammary gland. Consequently, although the concentrations of circulating estrogens in adult men are similar to that of adult women in the early follicular phase, breast development in men does not occur. Overt androgen deficiency or estrogen excess may be detected, whereas occasionally the ratio between the hormones is abnormal, despite the presence of normal concentrations of both sex hormones, resulting in a *relative androgen deficiency* or a *relative estrogen excess* (Rocheffort & Garcia, 1983). Furthermore, the activity of estrogen and androgen receptors might modify the hormonal signaling, leading to GM (Hellmann *et al.*, 2012).

Diminished androgen action may be a result of primary or secondary T deficiency, but in rare cases may also be due to the insensitivity of the androgen receptor. The major part of androgens is converted to estrogens by the enzyme aromatase located in the gonads, adipose tissue, and breast tissue (Mathur & Braunstein, 1997). Aromatase activity is increased by luteinizing

hormone (LH) stimulation, obesity, and alcohol, which are all common causes of GM (Ismail & Barth, 2001). Rare syndromes that alter enzymatic activity, such as aromatase excess syndrome, may also alter the estrogen-to-androgen balance either systematically (Stratakis *et al.*, 1998) or locally, in the breast tissue (Sasano *et al.*, 1996), leading to the development of GM.

Estrogen excess may follow increased production either from the gonads or the adrenal cortex, increased peripheral conversion of androgens to estrogens, or the administration of exogenous estrogens (Narula & Carlson, 2014). The negative feedback of estrogens on the secretion of LH from the pituitary gland further aggravates the derangement of the estrogen-to-androgen balance, which in turn leads to secondary T deficiency. Moreover, estrogens increase the sex hormone-binding globulin (SHBG) concentrations leading to even lower free T (fT) concentrations.

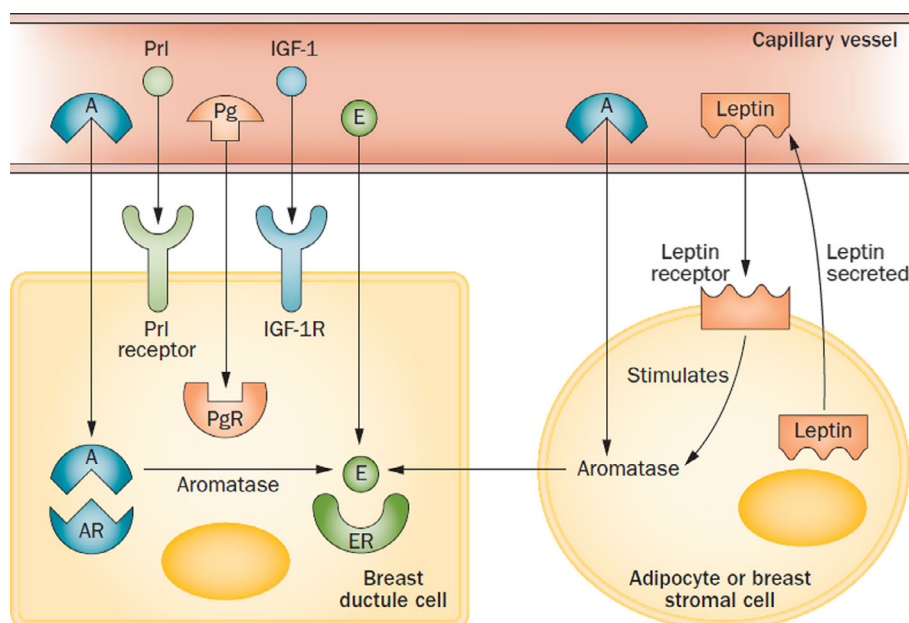
Conditions such as starvation and substantial weight loss have also been associated with GM as they may cause secondary T deficiency. As reproduction is considered an energy-consuming function, the body switches off the activity of the hypothalamic–pituitary–gonadal (HPG) axis in a generalized attempt to reduce energy expenditure, according to whether environmental circumstances are advantageous for reproduction or not (Jacobs, 1948; Smith *et al.*, 1975; Sattin *et al.*, 1984). By this mechanism, called ‘ontogenic regression’, all severe chronic diseases can potentially lead to the development of GM and may explain its extremely high prevalence in hospitalized or recovering men (Niewoehner & Nuttal, 1984).

CAUSES OF GYNECOMASTIA

Recommendations

R1. The presence of an underlying pathology should be considered in GM of adulthood. We recommend that the

Figure 2 The action of different hormones on breast tissue. Androgen receptor has an inhibitory effect on the development of breast cells, whereas other receptors have a stimulatory effect. A: androgen; AR: androgen receptor; E: estrogen; ER: estrogen receptor; Pg: progesterone; PgR: progesterone receptor; Prl: prolactin; IGF-1: insulin-like growth factor-1; IGF-1R: insulin-like growth factor-1 receptor. Reprinted by permission from: Springer Nature Customer Service Centre GmbH, Nat Rev Endocrinol, Gynaecomastia—pathophysiology, diagnosis and treatment. Narula & Carlson (2014).



identification of an apparent reason for GM in adulthood, including the use of medication known to be associated with GM, should not preclude a detailed investigation (1 ⊕⊕⊕○).

Evidence

There are several pathological causes of GM (Table 1); some of them common, whereas others are very rare. Figure 3 (adapted from Mieritz *et al.*, 2017) shows the distribution of causes detected in a clinical setting where men underwent a standardized workup (Mieritz *et al.*, 2017). The probability of detecting an underlying cause of GM seems to increase with advanced age, and, in approximately 10% of patients, more than one cause may exist. Thus, the identification of one apparent reason for GM, such as the use of a medication, should not preclude a detailed investigation (Mieritz *et al.*, 2017). In the proposed classification, various clinical entities are described and categorized according to the predominant endocrine derangement (e.g., low androgen concentrations), although they could fit into several.

Low androgen concentrations

Primary T deficiency

Primary testicular failure leads to low T production, which in turn evokes an elevation of LH output by the intact pituitary gland. The increased LH concentrations, though unable to completely ameliorate T deficiency, concomitantly enhance the activity of aromatase, resulting in an increased estrogen-to-androgen balance (Forest *et al.*, 1979). Causes of primary T deficiency include Klinefelter syndrome, orchitis, trauma, testicular tumors, chemotherapy/radiotherapy, and rare causes, such as enzymatic defects of T production and cases of 46,XY DSD.

Secondary T deficiency

In such cases, the production of T decreases due to reduced secretion of gonadotropin-releasing hormone (GnRH), LH, or both resulting in a decrease of the inhibitory effect of androgens

on the breast tissue. Causes for secondary T deficiency include isolated hypogonadotropic hypogonadism (IHH) such as Kallmann's syndrome, other genetic defects (e.g., PROP1 gene mutations), pituitary adenomas including hyperprolactinemia, and cranial irradiation. Opioid treatment or abuse can also lead to a centrally induced T deficiency (Gudin *et al.*, 2015).

Hyperprolactinemia

Prolactin is not considered to cause GM *per se*; however, it does so by suppressing GnRH secretion at the level of the hypothalamus, leading to secondary hypogonadism. Nonetheless, prolactin receptors have also been found in male breast tissue, and may also contribute to the development of GM (Ferreira *et al.*, 2008). Causes of hyperprolactinemia include pituitary adenomas, other lesions of the sellar region that cause destruction of the hypothalamic-pituitary dopaminergic pathway (the so-called 'stalk effect'), decreased PRL clearance due to renal disease, or drug-induced hyperprolactinemia due to various medications, especially antipsychotic drugs (Krause, 2012; Grigg *et al.*, 2017).

Renal disease

Both gonadal and hypothalamic/pituitary dysfunction can be induced by renal disease, resulting in T deficiency (Handelsman & Dong, 1993; Iglesias *et al.*, 2012). Moreover, chronic renal failure is commonly associated with hyperprolactinemia, as a combined result of pituitary derangement, decreased renal clearance, and might be further aggravated by medications frequently used in renal disease (e.g., metoclopramide, methyl-dopa) (Hou *et al.*, 1985).

Combination of high estrogen and androgen concentrations

Kennedy syndrome

This rare (1 in 40.000 men) syndrome is caused by an increased number of CAG (polyglutamine) repeats in the androgen receptor gene, which results in a lower sensitivity of the receptor (X-linked spinal and bulbar muscular atrophy) (La Spada *et al.*, 1992). Although there is phenotypic variability, in the classical phenotype, clinical signs of mild androgen deficiency such as GM are combined with both high T and LH concentrations, implying partial resistance to androgens. Neuromuscular problems (muscular weakness, atrophy, fasciculation) typically ensue after androgen resistance, at 40–50 years of age (Dejager *et al.*, 2002).

Androgen insensitivity syndrome

In this rare syndrome (1 : 20.000 males), a genetic defect in the androgen receptor (more than 500 different mutations have been reported) leads to decreased sensitivity for T (Quigley *et al.*, 1995; Gottlieb *et al.*, 2012). In patients with complete androgen insensitivity syndrome (CAIS), the phenotype at birth is that of normal girls, whereas patients with partial androgen insensitivity syndrome (PAIS) display signs of under-virilization in varying degrees, hypospadias, undescended testes, or bifid scrotum at birth (Quigley *et al.*, 1995). GM develops in the majority of patients during puberty and does not regress spontaneously (Hellmann *et al.*, 2012; Paris *et al.*, 2016).

Hyperthyroidism and hypothyroidism

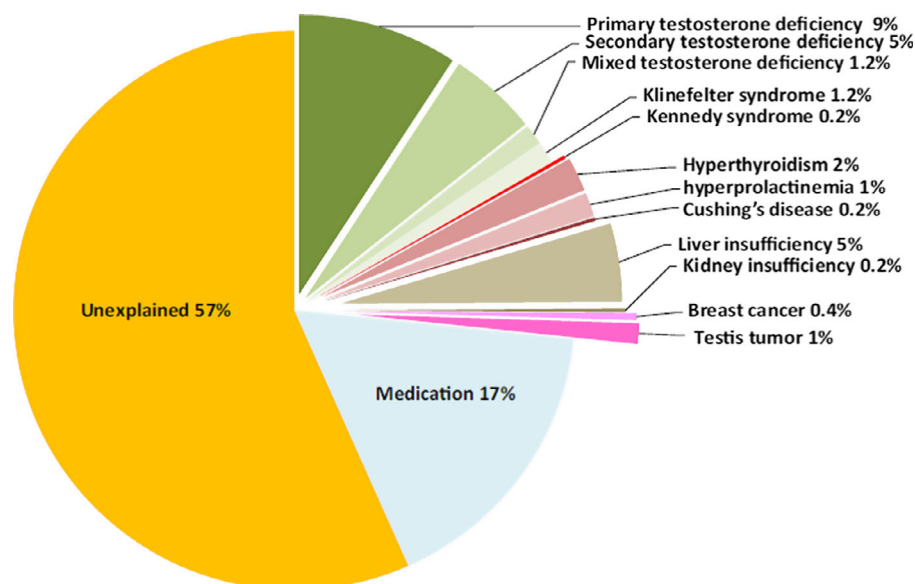
GM has been reported in 40% or more of men with hyperthyroidism (Ashkar *et al.*, 1970; Kidd *et al.*, 1979). Increased thyroid

Table 1 Causes of gynecomastia

Cause
Physiological and idiopathic
• Neonatal/infancy
• Pubertal
• Middle or advanced age
Pathological
• Medications
• Primary testosterone deficiency (particularly Klinefelter syndrome)
• Secondary testosterone deficiency
• Hyperthyroidism
• Neoplasms
• Testicular: originating from germ (secreting forms), Leydig or Sertoli cells
• Adrenal: androgen- or estrogen-secreting tumors
• Ectopic production of hCG
• Hepatic causes, malnutrition
• Renal causes
• Rare causes
• Enzymatic defects of testosterone production
• Androgen insensitivity syndromes
• True hermaphroditism
• Excessive extra-glandular aromatase activity
• Environmental polluting substances

hCG, human chorionic gonadotropin; T, testosterone.

Figure 3 Causes of gynecomastia with an adult debut in men with no substance abuse. Reprinted by permission from: Bioscientifica Limited, European journal of Endocrinology, Gynaecomastia in 786 adult men: clinical and biochemical findings, Mieritz *et al.* (2017).



hormone concentrations lead to increased production of SHBG, which in turn augments T binding. Consequently, LH secretion increases to maintain fT concentrations stable; this response, however, favors aromatization of androgens to estrogens, eventually disrupting estrogen-to-fT ratio (Forest *et al.*, 1979). Nonetheless, a direct stimulating effect of thyroid hormones on the activity of aromatase enzyme is also suggested (Kidd *et al.*, 1979). GM has also been reported in the hypothyroid state. In this case, the relative mechanisms include reduced T concentrations, most likely due to an elevation of prolactin as a result of enhanced thyroid-releasing hormone (TRH) stimulation (Krasas *et al.*, 2010).

Leydig and Sertoli cell tumors

Leydig cell tumors are benign testicular tumors secreting excessive amounts of T and 17 β -estradiol (E₂). T is further aromatized in the adipose tissue into E₂, which has lower affinity to SHBG compared to T, leading to an increased free E₂/T ratio (Bercovici *et al.*, 1981). To which degree Sertoli cell tumors are associated with the development of GM is questionable. Sertoli cell tumors typically emerge in syndromes such as Peutz-Jeghers and Carney complex (Kaltsas *et al.*, 2000).

Germ cell cancer

Germ cell tumors (testicular or extra-testicular), particularly those that contain choriocarcinoma components, may lead to the development of GM. The choriocarcinoma components secrete human chorionic gonadotropin (hCG) that stimulates Leydig cells. This stimulation leads to both T production and increased aromatase activity resulting in a relatively increased E₂ concentration (Forest *et al.*, 1979).

Abuse of anabolic androgenic steroids

Use of anabolic androgenic steroid (AAS) is frequent in elite athletes, and in recreational sports and bodybuilding; lifetime prevalence of AAS abuse is 6.4% for men (Nieschlag & Vorona, 2015). When considering the effects of these drugs, it must be

taken into consideration that they are often administered in very high and sometimes undefined doses, their purity might be unclear, and additional polypharmacy, including growth hormone, glucocorticoids, and hCG, is common. Moreover, 15% of nutritional supplements contain prohibited AAS, not declared on the supplement label (Geyer *et al.*, 2014). Some androgens (e.g., T and androstenedione) are aromatized, while others [dihydrotestosterone (DHT) and many synthetic androgens] cannot undergo aromatization. GM is a very common adverse effect of AAS abuse, especially concerning androgens that aromatize (Nieschlag & Vorona, 2015; Christou *et al.*, 2017). Moreover, most AAS regimens include hCG injections following high-dose AAS cycles to override HPG axis suppression and re-initiate T production. However, this may lead to or aggravate GM, due to an increased aromatase activity.

High estrogen concentrations

Cannabis

Cannabis abuse has been associated with GM in a few studies. The mechanism may include hyperprolactinemia and centrally induced hypogonadism (Mendelson *et al.*, 1974; Olusi, 1980; Mieritz *et al.*, 2017). An additional mechanism may be the similarity between the chemical structure of E₂ and cannabinoids that is the major active component in marijuana (Harmon & Aliapoulos, 1972).

Unintentional exposure to estrogens

Occasionally, GM may emerge by the accidental ingestion of oral contraceptive pills. In adult men, unintended exposure to estrogen may occur during intercourse with women using estrogen replacement therapy by vaginal route (DiRaimondo *et al.*, 1980). Environmental exposure to estrogen-like chemicals or phytoestrogens should also be considered (Henley *et al.*, 2007). However, soy proteins, despite containing high concentrations of phytoestrogens, have not been proved to cause GM (Giampietro *et al.*, 2004).

Obesity

Obesity is a condition associated with T deficiency of mainly secondary type (Matsumoto & Bremner, 2011; Boddi *et al.*, 2014), whereas aromatization of androgens occurs mainly in the adipose tissue; consequently, obese men have an increased estrogen-to-androgen ratio (Mathur & Braunstein, 1997). Local excessive fat deposition in obese men may worsen the clinical appearance.

Liver disease

GM is commonly reported in patients with liver cirrhosis (Cavanaugh *et al.*, 1990; Maruyama *et al.*, 1991). Several mechanisms may be involved; increased SHBG concentrations resulting in lower fT increased hepatic aromatization of T to estrogens and use of medication for liver cirrhosis with anti-androgenic action (e.g., spironolactone) (Olivo *et al.*, 1975; Maruyama *et al.*, 1991).

Alcohol abuse

Chronic alcohol abuse has been associated with primary T deficiency and GM, independently of liver involvement; ethanol is proposed to be a 'Leydig cell toxin' (Castilla-García *et al.*, 1987). The possible development of alcoholic liver disease further aggravates the clinical picture.

Other causes

Drug-induced GM

A broad spectrum of medications has been associated with GM. Generally, the documentation is sparse, and the reports use different definitions and methods to diagnose GM (Nuttall *et al.*, 2015). Furthermore, it is often not clear if it is the disease *per se*, the ontogenic regression related to the disease, or an adverse effect of the given drug that causes GM. Some drugs incline a risk of GM, such as those that have estrogenic properties, enhance estrogen production, or impede biosynthesis, action, or metabolism of androgens (e.g., α -reductase inhibitors used for benign prostate hyperplasia or GnRH agonists for prostate cancer) (Table 2). For other medications, such as spironolactone, although the association with GM is strong, the mechanism is not clear (Chapman *et al.*, 2007). A recent systematic review classified the medications that may cause GM in four categories by the level of evidence. A: proved causal role; B: highly probable role; and C and D: significant association could not be established (Krause, 2012). This classification is summarized in Table 2.

Re-feeding syndrome

During starvation or severe illness, secondary T deficiency gradually develops. However, estrogen concentrations remain relatively stable due to the preservation of adrenal precursors. Returning to a healthy diet leads to a re-activation of the HPG axis, in a way similar to puberty (Sattin *et al.*, 1984).

Non-gonadal tumors

Adrenal tumors

Adrenal tumors, mainly carcinomas (extremely rare, 0.5–2.0 per million), can secrete both estrogens and high amounts of adrenal androgens, which aromatize to estrogens. In this case, GM is usually of recent onset and progresses rapidly (LaFemina & Brennan, 2012).

Table 2 Medications associated with gynecomastia

Anti-androgens		Cardiovascular drugs	
Flutamide, bicalutamide	A	Calcium channel blockers	C
Finasteride, dutasteride	A	Amiodarone	C
Spironolactone	A	ACE inhibitors	C
Eplerenone	B	Digoxin	C
Ketoconazole	B	Drugs of abuse	
Lavender oil	C	Alcohol	B
Antibiotics		Amphetamines	C
Isoniazid	C	Heroin	C
Metronidazole	C	Marijuana	C
Anti-ulcer drugs		Metadone	C
Cimetidine	B	Hormones	
Ranitidine	B	Estrogens, clomiphene citrate	A
Proton pump inhibitors	B	hCG	B
Cancer chemotherapeutics		Anabolic steroids	C
Imatinib	C	GH	C
Methotrexate	C	Other	
Alkylating agents	C	Metoclopramide	A
Psychoactive drugs		HAART	B
Haloperidol	B	Phenytoin	C
Phenothiazines	B	Penicillamine	C
Diazepam	C	Theophylline	C

Causal role in GM by the level of evidence. A: proved causal role; B: highly probable role; and C: significant association could not be established (includes categories C and D of the original publication). Modified from: Krause (2012). ACE, angiotensin-converting enzyme; GH, growth hormone; HAART, highly active anti-retroviral therapy; hCG, human chorionic gonadotropin.

Androgen ablation therapy for prostate cancer

As prostate cancer is an androgen-dependent neoplasm, treatment strategies often involve medical castration (GnRH agonists), drugs that disrupt androgen production or action (anti-androgens), and occasionally bilateral orchiectomy. Therefore, GM is commonly observed among men treated for advanced prostate cancer (Alesini *et al.*, 2013).

Values and preferences

The recommendation to exclude pathological entities associated with GM in adults, even in the presence of an apparent modifiable cause, places a high value on detecting life-threatening organic causes of GM, such as neoplasia.

CLINICAL EVALUATION

Recommendations

- R2.** We suggest that the initial screening to rule out lipomastia, obvious breast cancer, or testicular cancer might be performed by a general practitioner or another non-specialist (2 ⊕○○○).
- R3.** We recommend that in those cases where a thorough diagnostic workup is warranted, it should be performed by a specialist (1 ⊕○○○).
- R4.** We recommend that the medical history should include information on the onset and duration of GM, sexual development and function, and administration or abuse of substances associated with GM (1 ⊕⊕⊕○).

Evidence

A suggested algorithm for the diagnostic approach of GM is presented in Fig. 4. A thorough diagnostic workup ought to be done only on those with adult-onset GM, provided that they are not in androgen ablation therapy (AAT) or are abusing AAS. AAT

or use of AAS does not exclude other underlying pathologies but make hormone profile evaluation virtually impossible (Nieschlag & Vorona, 2015). Exclusion of the presence of a testicular tumor may be sufficient.

The primary goal of the initial evaluation should be to confirm the presence of palpable glandular tissue and rule out the suspicion of malignant breast tumor or testicular tumor by palpation. It is essential to obtain a detailed medical history focusing on the onset and duration of GM as well as its previous occurrences. Persistence during adolescence or a new and rapidly developing condition may warrant further workup. Andrological history should include information on cryptorchidism, the onset of puberty, fertility status, and symptoms of T deficiency, including sexual functioning. Medications may lead to GM (Table 2). Thus, information on general illness, use of medications (both prescription and over-the-counter), use of AAS, alcohol, cannabis, and drug abuse (e.g., morphine and morphine-like substances) should also be noted (Braunstein, 2007).

Remarks

To which degree GM of puberty needs diagnostic workup is controversial; usually, it can be restricted to physical examination (Mieritz *et al.*, 2017). The initial screening of GM might be performed by a general practitioner or another non-specialist (depending on the local health system) to rule out the obvious presence of mammary or testicular cancer, in which cases the patients need to be directly referred to mammary surgeons or urologists. The workup of GM should be carried out by a specialist.

Values and preferences

Our strategy emphasizes that initial evaluation of GM may be carried out by a general practitioner, adequately trained to distinguish the minority of cases that warrant further evaluation by a specialist.

Physical examination

Recommendations

R5. We recommend that the physical examination should detect signs of under-virilization or systemic disease (1 ⊕⊕⊕⊕).

Evidence

The physical examination includes anthropometric measurements (e.g., height, weight, body mass index, waist circumference, waist-to-hip ratio) to quantify obesity. Assessment of body proportions to document eunuchoidism (arm span, and upper and lower body segment measurement) might be relevant among younger patients. Signs of under-virilization (face and body hair pattern, loss of muscle mass) should also be described. The physical examination also includes palpation of the thyroid gland and identification of signs of hyper- or hypothyroidism, hepatic or renal failure, and Cushing's disease.

Remarks

The general physical examination can suggest the underlying causes of GM. Frequently, more than one cause can contribute to the development of GM. Obesity, for example, is commonly

associated with hypogonadism (Boddi *et al.*, 2014), which can worsen an obesity-related pseudo-GM. Hence, the clinical suspicion should be confirmed with a specific diagnostic workup (see below).

Breast examination

Recommendations

We recommend that breast examination should confirm the presence of palpable glandular tissue to discriminate GM from lipomastia (pseudo-gynecomastia) and rule out the suspicion of malignant breast tumor (1 ⊕⊕⊕⊕).

Evidence

Breast examination has two main purposes: a) distinguish between true GM and pseudo-GM, and b) exclude breast carcinoma. Initial inspection and examination are performed with the patient in the sitting or lying position. Breast palpation is performed by squeezing the breast between the thumb and forefinger of the examiner (Fig. 5). The aim is to find the rim that distinguishes the outer limits of the gland to evaluate its size. The examination is completed with the patient in supine position with his hands clasped beneath his head, which facilitates palpation of the axillary regions (Braunstein, 2007; De Barros & Sampaio, 2012). Breast carcinoma is typically felt like a non-tender unilateral hard mass mostly located outside the areolar area, occasionally accompanied by skin changes (*peau d'orange*, ulceration), nipple retraction or bleeding, and possible axillary lymphadenopathy. Signs of carcinoma should prompt further investigations. Breast tenderness is a sign of recent hormone stimulation. Evaluation of the size of GM is based on the five breast stages described by Tanner: Stage 1 corresponds to normal male breast, whereas stage 5 represents the mature breast of an adult female (Marshall & Tanner, 1969). Location of the gland, size, galactorrhea (which, however, is exceptionally rare among GM patients), and whether the condition is unilateral or bilateral should be documented (Figs 1 and 6).

Remarks

In obese males, it may occasionally be difficult to distinguish between glandular and fat tissue (pseudo-GM). Glandular tissue is often bilateral and felt like a soft, elastic, or firm mass of tissue, sometimes tender, and in the majority of cases concentrically located behind the areola (Braunstein, 2007). In men who have had GM for more than 2–3 years, the presence of fibrosis that has developed may make it difficult to detect the presence of true GM. During puberty, GM is often associated with tenderness of the breast tissue.

Genital examination

Recommendations

R7. We recommend that the physical examination should include the examination of the genitalia to rule out the presence of a palpable testicular tumor and to detect testicular atrophy (1 ⊕⊕⊕⊕).

R8. We recommend that genitalia examination is aided by a testicular ultrasound, as the detection of a testicular tumor by palpation has low sensitivity (1 ⊕⊕○○).

Figure 4 Clinical and biochemical workup of adult men presenting with breast development. AAS: anabolic androgenic steroid; ALP: alkaline phosphatase; ALT: alanine aminotransferase; E₂: estradiol; IGF-1: insulin-like growth factor-1; LH: luteinizing hormone; SHBG: sex hormone-binding globulin; T: testosterone; T₃: triiodothyronine; T₄: thyroxine; TSH: thyroid-stimulating hormone. Reprinted by permission from: Bioscientifica Limited, European journal of Endocrinology, Gynaecomastia in 786 adult men: clinical and biochemical findings, Mieritz *et al.* (2017) (modified).

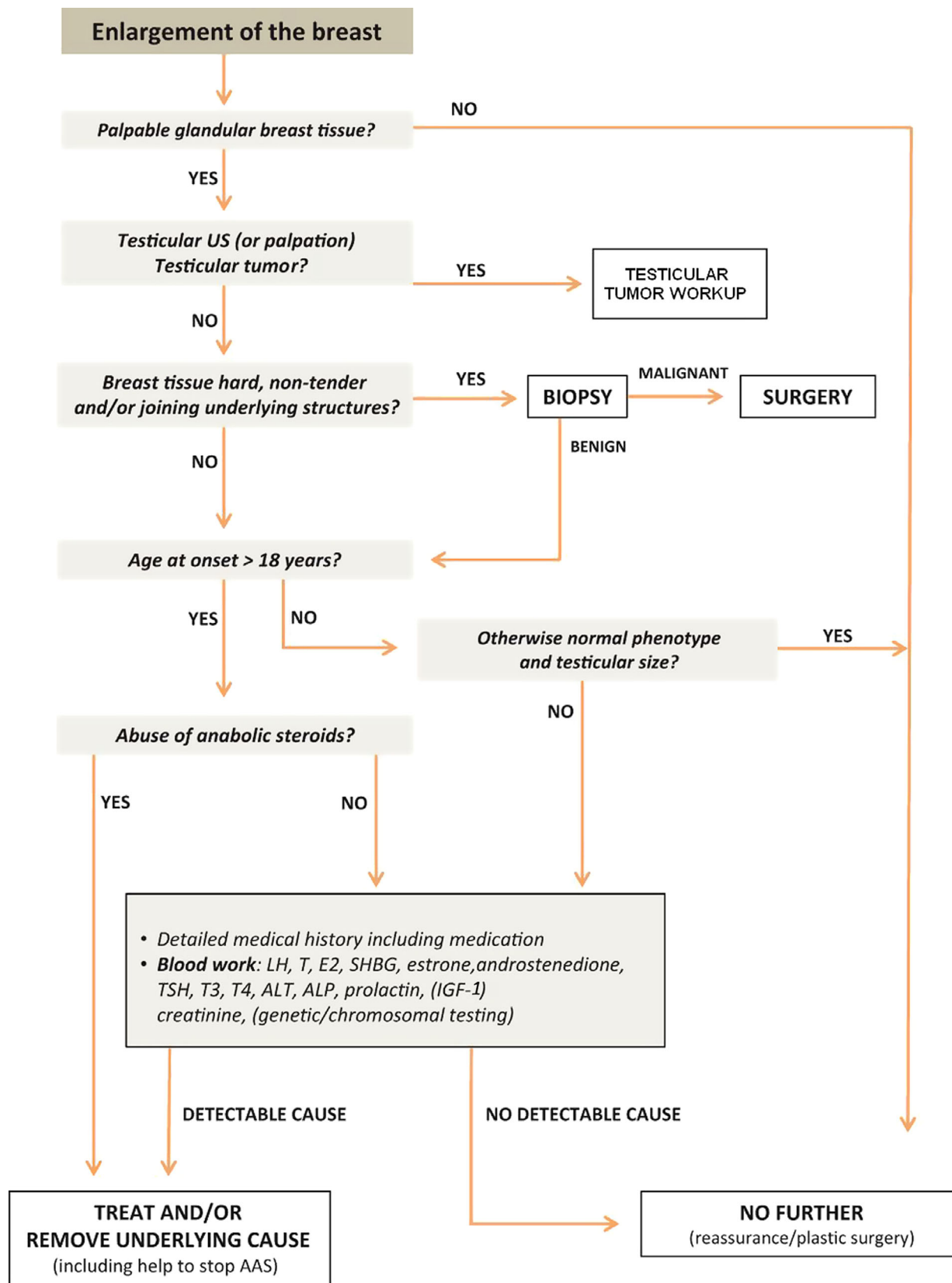


Table 3 Suggestions for the diagnostic approach of men with gynecomastia

Medical history collection

- Duration of gynecomastia, uni- or bilateral location, tenderness
- Previous occurrences of gynecomastia
- Previous or current cryptorchidism, fertility status
- Symptoms of testosterone deficiency, hyperthyroidism, or systemic illnesses
- Complete list of medication, use of recreational drugs and/or supplements

Physical examination

- Uni- or bilateral location, size, tenderness
- Height, weight, and body mass index
- Thyroid palpation
- General (signs of systemic illnesses) and genital (testicular size, consistency) physical examination

First-level laboratory blood tests and instrumental investigations

- LH, FSH, T, E₂, SHBG
- β -hCG
- TSH
- Prolactin
- Liver function: SGOT, SGPT, albumin
- Renal function: creatinine, urea
- Testicular ultrasound scan

Additional laboratory blood investigations^a

- DHEA-S, Δ_4 -A
- Karyotype
- DNA for genetic analysis, such as PCR for androgen receptor

Δ_4 -A, Δ_4 -androstenedione; DHEA-S, dehydroepiandrosterone-sulfate; E₂, 17 β -estradiol; FSH, follicle-stimulating hormone; hCG, human chorionic gonadotropin; LH, luteinizing hormone; PCR, polymerase chain reaction; SHBG, sex hormone-binding globulin; SGOT, serum glutamic oxaloacetic transaminase; SGPT, serum glutamate-pyruvate transaminase; T, testosterone; TSH, thyroid-stimulating hormone. ^aNeeded when the basic investigation has not revealed the cause of the GM.

Evidence

The genital examination includes evaluation of pubic hair, penile size, scrotal development, testicular size, consistency, and surface. Testicular volume can be evaluated by the use of a Prader orchidometer and by scrotal ultrasound scan. Testicular palpation may reveal the presence of abnormal areas, which should be confirmed by the ultrasound scan (Carmignani *et al.*, 2003; Avci *et al.*, 2008).

Remarks

Most of the testicular tumors, whether benign or malignant, are small and hence not palpable at the time of referral, a fact that renders ultrasound scan mandatory in patients with GM (Lotti & Maggi, 2015).

Values and preferences

Our recommendations on physical examination, including breast and genitalia, place a high value on the thorough search for signs of pathological entities associated with GM, especially neoplasia.

LABORATORY EVALUATION

Defining a set of evaluations may be an efficient way to reduce the duration and costs until a conclusion can be reached.

Hormonal evaluation

- R9.** We suggest that a set of evaluations may include T, E₂, SHBG, LH, follicle-stimulating hormone (FSH), thyroid-

stimulating hormone (TSH), prolactin, hCG, alpha-fetal protein (AFP), and liver and renal function tests (2 ⊕⊕○○).

Evidence

The basic hormonal evaluation includes T, E₂, SHBG, LH, FSH, TSH, prolactin, and tumor markers of testicular or extragonadal cancer (hCG and AFP). If Cushing's disease, hepatic or renal failure, is suspected, the appropriate laboratory tests should be performed.

Increased gonadotropin concentrations combined with low T concentrations are suggestive of primary T deficiency. High LH concentrations in the presence of normal T (compensated T deficiency, Fig. 7) may also cause GM due to the aromatase-stimulating effect of LH (Forest *et al.*, 1979). In cases of testicular or ectopic hCG production, T concentrations are usually high-normal and LH and FSH concentrations suppressed.

Remarks

Low total T concentrations are not always indicative of T deficiency due to changes in SHBG concentrations. Thus, measurement of SHBG in addition to total T and, in equivocal cases, assessment of fT should be carried out (Wu *et al.*, 2010). The current immunoassays of fT and E₂ in the males still lack the desired accuracy, and results should be interpreted with caution (Morales *et al.*, 2012; Handelsman *et al.*, 2014). Preferably, fT should be either measured directly by assays including equilibrium dialysis or, alternatively, calculated indirectly by using one of the available accurate formulas (Bhasin *et al.*, 2018). Regarding E₂ measurement, liquid chromatography–tandem mass spectrometry (LC-MS/MS) is more accurate and should be preferred over currently available immunoassays (Huhtaniemi *et al.*, 2012). Furthermore, it may occasionally be insufficient to conclude about hormonal disturbances based on whether individual hormones are within the reference range. As an example, E₂ might be high normal and T low normal, but the E₂-T ratio increased. Reference levels are population-based, and there are no clear biological thresholds; subtle but relevant changes may be overlooked if the evaluation of hormone levels is merely based on whether they lie 'outside' the laboratory reference range. Thus, great care should be taken, which is why we suggest broad screening, including the screening of other organ systems to increase the diagnostic sensitivity. Suggestions for the diagnostic approach of men with gynecomastia are listed in Table 3.

Breast imaging

- R10.** We suggest that breast imaging may offer assistance, where the clinical examination is equivocal (2 ⊕⊕○○).

- R11.** We suggest that, if the clinical picture is suspicious for a malignant lesion, core needle biopsy should be performed rather than breast imaging (2 ⊕⊕○○).

Evidence

In the vast majority of cases, the clinical picture of GM is informative, and there is no need to perform imaging (Chau *et al.*, 2016). However, imaging may offer valuable assistance in case of obese men where breast examination and distinction from lipomastia can be difficult or in cases with fibrosis/hyalinization. Mammography has been shown to be the most sensitive and

Figure 5 Technique and findings in breast palpation. Reprinted by permission from Massachusetts Medical Society, The New England Journal of Medicine, Gynecomastia, Braunstein (2007).

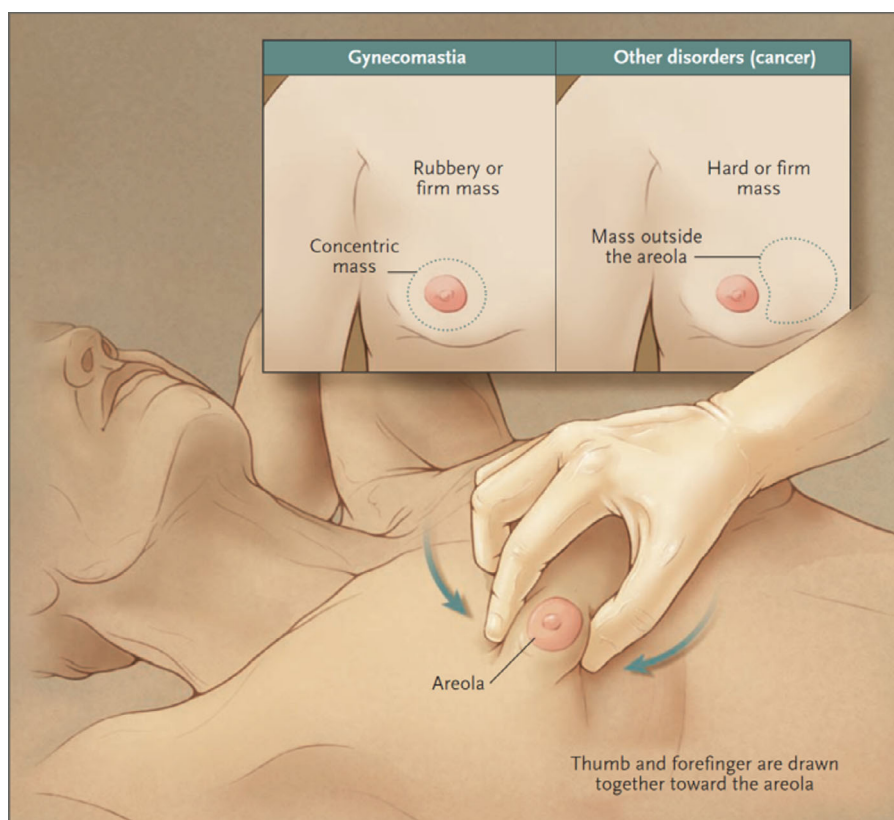
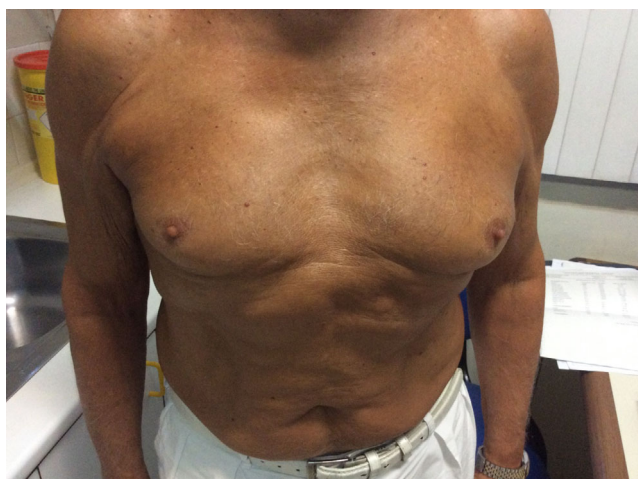

Figure 6 Advanced age gynecomastia of a 75-year-old man. Breast enlargement appeared soon after the administration of dutasteride for benign prostate hypertrophy (courtesy of Dr. G. Kanakis).



ultrasound, the most specific technique for the detection of malignancy, whereas ultrasound is more convenient (Muñoz Carrasco *et al.*, 2010).

Remarks

If the clinical picture is suspicious of a malignant lesion, the diagnostic approach should opt directly to perform a core needle biopsy (Hines *et al.*, 2007).

Values and preferences

Our recommendations on hormonal evaluation place a high value on identifying those men who present GM in the setting of an overt endocrinological disorder, whereas the recommendations on breast imaging place a high value on avoiding unnecessary imaging studies that may delay the acquisition of a histological diagnosis in a suspicious lesion.

MANAGEMENT

Any underlying pathology should be treated, if possible (e.g., T substitution in case of T deficiency, and treatment of hyperthyroidism or hyperprolactinemia). T treatment is effective only in patients with proven T deficiency, as in eugonadal men it may worsen GM due to enhanced aromatization to E₂ (Forest *et al.*, 1979; Wu *et al.*, 1996). If a pharmaceutical substance is suspected to be the cause, the medication should be changed or discontinued, if possible. In the case of AAS abuse, cessation of the substance should be encouraged.

Watchful waiting

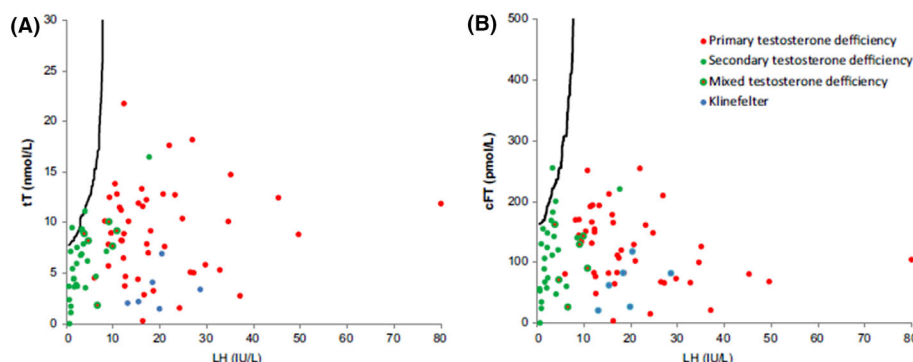
Recommendations

R12. We recommend watchful waiting after treatment of underlying pathology or discontinuation of the administration/abuse of substances associated with GM (1 ⊕⊕○○).

Evidence

In cases of GM of puberty or GM of adulthood with negative physical and hormonal investigations, there is a fair chance that

Figure 7 Ratios of total testosterone (tT) and calculated free testosterone (cFT) according to luteinizing hormone (LH) in men with primary (red), secondary (green), and mixed (red/green) testosterone deficiency and Klinefelter syndrome (blue). 95% of healthy Danish adult men are on the left side of the black line. Reprinted by permission from: Bioscientifica Limited, European journal of Endocrinology, Gynaecomastia in 786 adult men: clinical and biochemical findings, Mieritz *et al.* (2017).



the condition will disappear spontaneously, especially if it is of recent onset (Nydick *et al.*, 1961; Lee, 1975; Biro *et al.*, 1990; Mieritz *et al.*, 2017).

Remarks

Particular attention should be paid to GM in boys of prepubertal age, a rare finding, which is not anticipated by normal hormone fluctuations and warrants thorough evaluation to rule out an underlying pathology (Einav-Bachar *et al.*, 2004).

Medical treatment

Recommendations

- R13.** We recommend that T treatment should be offered only to men with proven testosterone deficiency (1 ⊕⊕⊕○).
- R14.** We do not recommend the use of selective estrogen receptor modulators (SERMs), aromatase inhibitors (AIs), or non-aromatizable androgens in the treatment of GM in general. (1 ⊕⊕○○).

Evidence

In cases of overt T deficiency, T replacement has been reported to ameliorate GM (Dobs *et al.*, 1999); however, this is not the case in eugonadal men, where it is reported to aggravate or even produce GM due to aromatization of excessive T to E₂ (Wu *et al.*, 1996). Percutaneous treatment with non-aromatizable androgens, such as DHT, has also been reported to be effective in small series of patients (Kuhn *et al.*, 1983; Eberle *et al.*, 1986; Benveniste *et al.*, 2001).

SERMs, such as tamoxifen, raloxifene, and clomiphene citrate or AIs, have been tested in the treatment of idiopathic GM, considering the inhibitory action they exert on breast tissue (Lawrence *et al.*, 2004).

Tamoxifen is the best-studied SERM. It has been used in GM of puberty with partial response in the vast majority of boys (90%) but a complete response in <10% (Derman *et al.*, 2003). Similarly, in adults with GM, a reduction in tenderness and breast size has been reported with tamoxifen, but no patient experienced complete remission (Khan *et al.*, 2004; James *et al.*, 2012). If no pathology has been shown and pain remains a problem, further diagnostic procedures ought to be undertaken, and alternative diagnoses (e.g., hematoma or infections) should be ruled out rather than treating with SERMs.

In the rare cases of increased aromatase activity *per se*, which can be identified by the presence of elevated estrogen concentrations, treatment with AIs may be considered as an alternative to surgical treatment (Braunstein, 1999). Nevertheless, evidence regarding their efficacy is low, and the long-term adverse effects of AIs on bone metabolism have to be considered (Plourde *et al.*, 2004; Riepe *et al.*, 2004; Mauras *et al.*, 2009).

Remarks

Limited information from randomized controlled trials (RCTs) is available for the use of SERMs and DHT in the treatment of idiopathic GM. DHT has not been tested in RCTs. The only RCT including SERMs in the treatment of GM did not prove any benefit (McDermott *et al.*, 1990). In accordance with these results, the use of SERMs is not justified for the treatment of GM with the possible exception of tamoxifen in cases of painful GM of recent onset as it offers rapid relief from pain, regardless of the magnitude of response. In contrary, there is a substantial body of evidence that supports the use of SERMs or AIs for the prevention of GM in patients with prostate cancer undergoing AAT (Boccardo *et al.*, 2005; Dobs & Darkes, 2005). An alternative modality is low-dose prophylactic radiotherapy (PRT) (Dicker, 2003), which, although less effective, is more practical, as few short-term applications are required.

Regarding safety issues, PRT has been associated with local skin rash/irritation and asthenia whereas SERMs (tamoxifen in particular) with constipation/diarrhea and pruritus. All these adverse effects are of mild degree and resolve spontaneously. No long-term sequel (e.g., secondary malignancy, relapse of prostate cancer) has been documented for either therapy (Perdonà *et al.*, 2005).

Surgical treatment

Recommendations

- R15.** We suggest surgical treatment only for patients with long-lasting GM, which does not regress spontaneously or following medical therapy. The extent and type of surgery depend on the size of breast enlargement, and the amount of adipose tissue (2 ⊕⊕○○).

Evidence

Only a small proportion of patients with GM will need surgical treatment. The vast majority of patients either will experience

spontaneous regression or will receive specific treatment that will relieve the underlying pathology. The classical surgical approach is the nipple-sparing subcutaneous mastectomy (Let-terman & Schurter, 1976; Webster, 1980). However, suction lipectomy has proved helpful for tapering the edges, and it may be used as the sole procedure, in mild GM (Sarkar *et al.*, 2014). It is essential to preserve a button of tissue under the areola to maintain a sufficient blood supply and to prevent the nipple from retracting (Boljanovic *et al.*, 2003). In severe GM, skin resection is often necessary in combination with transposition of the nipple–areola complex. The most frequent surgical complications are numbness of the nipple and adherence of the areola to the pectoral muscle (Rahmani *et al.*, 2011).

Remarks

Any surgical treatment should not be offered until after an observation period has been allowed. Clinical practice may vary according to local algorithms and legislation (e.g., in Denmark, surgical treatment of adult-onset GM will usually not be offered in public hospitals unless the GM has lasted for at least one year after treatment of the underlying pathology or has lasted at least one year without the detection of any pathology). In the case of pubertal GM, the observation period may be extended up to two years of persistence, until surgery is recommended (Bannayan & Hajdu, 1972; Mieritz *et al.*, 2017).

Persistent GM may have significant psychosocial and psychological consequences. Available literature suggests the association of GM with depression, anxiety, low self-esteem and body image concerns, issues that may lead patients to maladaptive coping mechanisms such as wrapping of the chest, walking with slumped shoulders and arms crossed, and eventually restriction of physical and social activities (Ordaz & Thompson, 2015). It should be noted though that most of the relevant data refer to adolescents, with other populations being less represented (Kinsella *et al.*, 2012). In such cases of GM where the disease causes considerable cosmetic and psychological distress, surgical treatment is justified (Mathur & Braunstein, 1997; Kasielska & Antoszewski, 2011; Rew *et al.*, 2015). Older studies suggest better psychological post-operative adjustment when surgery is combined with psychotherapy (Schonfeld, 1962); however, recent data are missing.

Values and preferences

Our recommendations on medical management of GM reflect our preference to avoid empirical therapies that lack a substantial body of evidence. Instead, we promote watchful waiting after the withdrawal of detrimental factors and/or the correction of underlying pathologies and place a high value on conserving T replacement therapy for those with unequivocally confirmed T deficiency. Our recommendation on surgical treatment stresses that this is the therapy of choice in the presence of persistent pubertal GM, especially when associated with significant psychological distress or when the correction of the predisposing factor does not result in remission of GM after a sufficient period of surveillance (usually more than one year).

CONCLUSIONS

GM is a common condition associated with benign hormonal processes of maturation of the male adolescent in the majority of cases. On the other hand, GM of the elderly is

more often associated with underlying pathological conditions. The assessment of GM should aim the detection of such conditions or the administration/abuse of aggravating substances as well as the exclusion of the very rare male breast cancer. The cornerstones of assessment are thorough medical history and physical examination including the breast and genitalia (supported by testicular ultrasound). Laboratory investigations may reveal underlying systematic disorders, whereas the role of breast imaging is still debated: Core needle biopsy should be sought in any clinical suspicious breast lesion. Watchful waiting and reassurance are reasonable options after underlying pathology, or the administration/abuse of substances associated with GM has been excluded or treated. The use of medical regimens, including SERMS, AIs, or DHT, still lacks substantial evidence to recommend their generalized use, while surgical treatment remains the therapy of choice for patients with long-lasting GM.

REFERENCES

- Akgül S, Kanbur N & Derman O. (2014) Pubertal gynecomastia: what about the remaining 10%? *J Pediatr Endocrinol Metab* 27, 1027–1028.
- Alesini D, Iacovelli R, Palazzo A, Altavilla A, Risi E, Urbano F, Manai C, Passaro A, Magri V & Cortesi E. (2013) Multimodality treatment of gynecomastia in patients receiving antiandrogen therapy for prostate cancer in the era of abiraterone acetate and new antiandrogen molecules. *Oncology* 84, 92–99.
- Ashkar FS, Smoak WM, Gilson AJ & Miller R. (1970) Gynecomastia and mastoplasia in Graves' disease. *Metabolism* 19, 946–951.
- Avci A, Erol B, Eken C & Ozgok Y. (2008) Nine cases of nonpalpable testicular mass: an incidental finding in a large scale ultrasonography survey. *Int J Urol* 15, 833–836.
- Bannayan GA & Hajdu SI. (1972) Gynecomastia: clinicopathologic study of 351 cases. *Am J Clin Pathol* 57, 431–437.
- Benveniste O, Simon A & Herson S. (2001) Successful percutaneous dihydrotestosterone treatment of gynecomastia occurring during highly active antiretroviral therapy: four cases and a review of the literature. *Clin Infect Dis* 33, 891–893.
- Bercovici JP, Tater D, Khoury S, Charles JF, Floch J & Leroy JP. (1981) Leydig cell tumor with gynecomastia: hormonal effects of an estrogen-producing tumor. *J Clin Endocrinol Metab* 53, 1291–1296.
- Bhasin S, Cunningham GR, Hayes FJ, Matsumoto AM, Snyder PJ, Swerdloff RS, Montori VM & Task Force, Endocrine Society. (2018) Task Force, Testosterone therapy in men with androgen deficiency syndromes: an Endocrine Society clinical practice guideline. *J Clin Endocrinol Metab* 103, 1–30.
- Biesma HD, Schouten PC, Lacle MM, Sanders J, Brugman W, Kerkhoven R, Mandjes I, van der Groep P, van Diest PJ & Linn SC. (2015) Copy number profiling by array comparative genomic hybridization identifies frequently occurring BRCA2-like male breast cancer. *Genes Chromosom Cancer* 54, 734–744.
- Biro FM, Lucky AW, Huster GA & Morrison JA. (1990) Hormonal studies and physical maturation in adolescent gynecomastia. *J Pediatr* 116, 450–455.
- Boccardo F, Rubagotti A, Battaglia M, Di Tonno P, Selvaggi FP, Conti G, Comeri G, Bertaccini A, Martorana G, Galassi P, Zattoni F, Macchiarella A, Siragusa A, Muscas G, Durand F, Potenzoni D, Manganelli A, Ferraris V & Montefiore F. (2005) Evaluation of tamoxifen and anastrozole in the prevention of gynecomastia and breast pain induced by bicalutamide monotherapy of prostate cancer. *J Clin Oncol* 23, 808–815.
- Boddi V, Barbaro V, McNieven P, Maggi M & Rotella CM. (2014) Present and future association between obesity and hypogonadism in Italian male. *Arch Ital Di Urol E Androl* 86, 26–32.

- Boljanovic S, Axelsson CK & Elberg JJ. (2003) Surgical treatment of gynecomastia: liposuction combined with subcutaneous mastectomy. *Scand J Surg* 92, 160–162.
- Braunstein GD. (1999) Aromatase and gynecomastia. *Endocr Relat Cancer* 6, 315–324.
- Braunstein GD. (2007) Gynecomastia. *N Engl J Med* 357, 1229–1237.
- Brinton LA. (2011) Breast cancer risk among patients with Klinefelter syndrome. *Acta Paediatr* 100, 814–818.
- Carmignani L, Gadda F, Gazzano G, Nerva F, Mancini M, Ferruti M, Bulfamante G, Bosari S, Coggi G, Rocco F & Colpi GM. (2003) High incidence of benign testicular neoplasms diagnosed by ultrasound. *J Urol* 170, 1783–1786.
- Castilla-García A, Santolaria-Fernández FJ, González-Reimers CE, Batista-López N, González-García C, Jorge-Hernández JA & Hernández-Nieto L. (1987) Alcohol-induced hypogonadism: reversal after ethanol withdrawal. *Drug Alcohol Depend* 20, 255–260.
- Cavanaugh J, Niewoehner CB & Nuttall FQ. (1990) Gynecomastia and cirrhosis of the liver. *Arch Intern Med* 150, 563–565.
- Chapman N, Dobson J, Wilson S & Anglo-Scandinavian Cardiac Outcomes Trial Investigators. (2007) Effect of spironolactone on blood pressure in subjects with resistant hypertension. *Hypertension* 49, 839–845.
- Chau A, Jafarian N & Rosa M. (2016) Male breast: clinical and imaging evaluations of benign and malignant entities with histologic correlation. *Am J Med* 129, 776–791.
- Christou MA, Christou PA, Markozannes G, Tsatsoulis A, Mastorakos G & Tigas S. (2017) Effects of anabolic androgenic steroids on the reproductive system of athletes and recreational users: a systematic review and meta-analysis. *Sports Med* 47, 1869–1883.
- De Barros ACSD & Sampaio MDCM. (2012) Gynecomastia: physiopathology, evaluation and treatment. *Sao Paulo Med J* 130, 187–197.
- Dejager S, Bry-Gauillard H, Bruckert E, Eymard B, Salachas F, LeGuern E, Tardieu S, Chadarevian R, Giral P & Turpin G. (2002) A comprehensive endocrine description of Kennedy's disease revealing androgen insensitivity linked to CAG repeat length. *J Clin Endocrinol Metab* 87, 3893–3901.
- Derman O, Kanbur NO & Kutluk T. (2003) Tamoxifen treatment for pubertal gynecomastia. *Int J Adolesc Med Health* 15, 359–363.
- Dicker AP. (2003) The safety and tolerability of low-dose irradiation for the management of gynaecomastia caused by antiandrogen monotherapy. *Lancet Oncol* 4, 30–36.
- DiRaimondo CV, Roach AC & Meador CK. (1980) Gynecomastia from exposure to vaginal estrogen cream. *N Engl J Med* 302, 1089–1090.
- Dobs AS, Meikle AW, Arver S, Sanders SW, Caramelli KE & Mazer NA. (1999) Pharmacokinetics, efficacy, and safety of a permeation-enhanced testosterone transdermal system in comparison with bi-weekly injections of testosterone enanthate for the treatment of hypogonadal men. *J Clin Endocrinol Metab* 84, 3469–3478.
- Dobs A & Darkes MJM. (2005) Incidence and management of gynecomastia in men treated for prostate cancer. *J Urol* 174, 1737–1742.
- Eberle AJ, Sparrow JT & Keenan BS. (1986) Treatment of persistent pubertal gynecomastia with dihydrotestosterone heptanoate. *J Pediatr* 109, 144–149.
- Einav-Bachar R, Phillip M, Aurbach-Klipper Y & Lazar L. (2004) Prepubertal gynaecomastia: aetiology, course and outcome. *Clin Endocrinol (Oxf)* 61, 55–60.
- Fentiman IS, Fourquet A & Hortobagyi GN. (2006) Male breast cancer. *Lancet* 367, 595–604.
- Ferreira M, Mesquita M, Quaresma M & André S. (2008) Prolactin receptor expression in gynaecomastia and male breast carcinoma. *Histopathology* 53, 56–61.
- Forest MG, Lecoq A & Saez JM. (1979) Kinetics of human chorionic gonadotropin-induced steroidogenic response of the human testis. II. Plasma 17 alpha-hydroxyprogesterone, delta4-androstenedione, estrone, and 17 beta-estradiol: evidence for the action of human chorionic gonadotropin on interm. *J Clin Endocrinol Metab* 49, 284–291.
- Georgiadis E, Papandreou L, Evangelopoulou C, Aliferis C, Lymberis C, Panitsa C & Batrinos M. (1994) Incidence of gynaecomastia in 954 young males and its relationship to somatometric parameters. *Ann Hum Biol* 21, 579–587.
- Geyer H, Schänzer W & Thevis M. (2014) Anabolic agents: recent strategies for their detection and protection from inadvertent doping. *Br J Sports Med* 48, 820–826.
- Giampietro PG, Bruno G, Furcolo G, Casati A, Brunetti E, Spadoni GL & Galli E. (2004) Soy protein formulas in children: no hormonal effects in long-term feeding. *J Pediatr Endocrinol Metab* 17, 191–196.
- Gottlieb B, Beitel LK, Nadarajah A, Paliouras M & Trifiro M. (2012) The androgen receptor gene mutations database: 2012 update. *Hum Mutat* 33, 887–894.
- Grigg J, Worsley R, Thew C, Gurvich C, Thomas N & Kulkarni J. (2017) Antipsychotic-induced hyperprolactinemia: synthesis of world-wide guidelines and integrated recommendations for assessment, management and future research. *Psychopharmacology* 234, 3279–3297.
- Gudin JA, Laitman A & Nalamachu S. (2015) Opioid related endocrinopathy: Table 1. *Pain Med* 16(suppl 1), S9–S15.
- Handelsman DJ & Dong Q. (1993) Hypothalamo-pituitary gonadal axis in chronic renal failure. *Endocrinol Metab Clin North Am* 22, 145–161.
- Handelsman D, Newman JD, Jimenez M, McLachlan R, Sartorius G & Jones GRD. (2014) Performance of direct estradiol immunoassays with human male serum samples. *Clin Chem* 60, 510–517.
- Harmon J & Aliapoulos MA. (1972) Gynecomastia in marihuana users. *N Engl J Med* 287, 936.
- Hellmann P, Christiansen P, Johannsen TH, Main KM, Duno M & Juul A. (2012) Male patients with partial androgen insensitivity syndrome: a longitudinal follow-up of growth, reproductive hormones and the development of gynaecomastia. *Arch Dis Child* 97, 403–409.
- Henley DV, Lipson N, Korach KS & Bloch CA. (2007) Prepubertal gynecomastia linked to lavender and tea tree oils. *N Engl J Med* 356, 479–485.
- Hines SL, Tan WW, Yasrebi M, DePeri ER & Perez EA. (2007) The role of mammography in male patients with breast symptoms. *Mayo Clin Proc* 82, 297–300.
- Hou SH, Grossman S & Molitch ME. (1985) Hyperprolactinemia in patients with renal insufficiency and chronic renal failure requiring hemodialysis or chronic ambulatory peritoneal dialysis. *Am J Kidney Dis* 6, 245–249.
- Huhtaniemi IT, Tajar A, Lee DM, O'Neill TW, Finn JD, Bartfai G & EMAS Group. (2012) Comparison of serum testosterone and estradiol measurements in 3174 European men using platform immunoassay and mass spectrometry; relevance for the diagnostics in aging men. *Eur J Endocrinol* 166, 983–991.
- Iglesias P, Carrero JJ & Díez JJ. (2012) Gonadal dysfunction in men with chronic kidney disease: clinical features, prognostic implications and therapeutic options. *J Nephrol* 25, 31–42.
- Ismail AA & Barth JH. (2001) Endocrinology of gynaecomastia. *Ann Clin Biochem* 38, 596–607.
- Jacobs EC. (1948) Effects of starvation on sex hormones in the male. *J Clin Endocrinol Metab* 8, 227–232.
- James R, Ahmed F & Cunnick G. (2012) The efficacy of tamoxifen in the treatment of primary gynecomastia: an observational study of tamoxifen versus observation alone. *Breast J* 18, 620–621.
- Jayasinghe Y, Cha R, Horn-Ommen J, O'Brien P & Simmons PS. (2010) Establishment of normative data for the amount of breast tissue present in healthy children up to two years of age. *J Pediatr Adolesc Gynecol* 23, 305–311.
- Kaltsas G, Kanakis G & Chrousos G. (2000) Carney's Complex. Endotext.

- Kanhai RC, Hage JJ, van Diest PJ, Bloemena E & Mulder JW. (2000) Short-term and long-term histologic effects of castration and estrogen treatment on breast tissue of 14 male-to-female transsexuals in comparison with two chemically castrated men. *Am J Surg Pathol* 24, 74–80.
- Kasielska A & Antoszewski B. (2011) Effect of operative treatment on psychosocial problems of men with gynaecomastia. *Pol Przegl Chir* 83, 614–621.
- Khan HN, Rampaul R & Blamey RW. (2004) Management of physiological gynaecomastia with tamoxifen. *Breast* 13, 61–65.
- Kidd GS, Glass AR & Vigersky RA. (1979) The hypothalamic-pituitary-testicular axis in thyrotoxicosis. *J Clin Endocrinol Metab* 48, 798–802.
- Kilic M, Kanbur N, Derman O, Akgül S & Kutluk T. (2011) The relationship between pubertal gynaecomastia, prostate specific antigen, free androgen index, SHBG and sex steroids. *J Pediatr Endocrinol Metab* 24, 61–67.
- Kinsella C, Landfair A, Rottgers SA, Cray JJ, Weidman C, Deleyiannis FW-B, Grunwaldt L & Losee JE. (2012) The psychological burden of idiopathic adolescent gynaecomastia. *Plast Reconstr Surg* 129, 1–7.
- Knorr D & Bidlingmaier F. (1975) Gynaecomastia in male adolescents. *Clin Endocrinol Metab* 4, 157–171.
- Krassas GE, Poppe K & Glinier D. (2010) Thyroid function and human reproductive health. *Endocr Rev* 31, 702–755.
- Krause W (2012) Drug-inducing gynaecomastia - a critical review. *Andrologia* 44(Suppl.1), 621–626.
- Kuhn JM, Roca R, Laudat M, Rieu M, Luton J & Bricaire H. (1983) Studies on the treatment of idiopathic gynaecomastia with percutaneous dihydrotestosterone. *Clin Endocrinol (Oxf)* 19, 513–520.
- Kumanov P, Deepinder F, Robeva R, Tomova A, Li J & Agarwal A. (2007) Relationship of adolescent gynaecomastia with varicocele and somatometric parameters: a cross-sectional study in 6200 healthy boys. *J Adolesc Health* 41, 126–131.
- La Spada AR, Roling DB, Harding AE, Warner CL, Spiegel R, Hausmanowa-Petrusewicz I, Yee WC & Fischbeck KH. (1992) Meiotic stability and genotype-phenotype correlation of the trinucleotide repeat in X-linked spinal and bulbar muscular atrophy. *Nat Genet* 2, 301–304.
- LaFemina J & Brennan MF. (2012) Adrenocortical carcinoma: past, present, and future. *J Surg Oncol* 106, 586–594.
- Laitman Y, Keinan Boker L, Liphitz I, Weissglas-Volkov D, Litz-Philipsborn S, Schayek H & Friedman E. (2015) Cancer risks in Jewish male BRCA1 and BRCA2 mutation carriers. *Breast Cancer Res Treat* 150, 631–635.
- Lawrence SE, Faught KA, Vethamuthu J & Lawson ML. (2004) Beneficial effects of raloxifene and tamoxifen in the treatment of pubertal gynaecomastia. *J Pediatr* 145, 71–76.
- Lee PA. (1975) The relationship of concentrations of serum hormones to pubertal gynaecomastia. *J Pediatr* 86, 212–215.
- Lee KO, Chua DY & Cheah JS. (1990) Oestrogen and progesterone receptors in men with bilateral or unilateral pubertal macromastia. *Clin Endocrinol (Oxf)* 32, 101–105.
- Letterman G & Schurter M. (1976) A comparison of modern methods of reduction mammoplasty. *South Med J* 69, 1367–1371.
- Lotti F & Maggi M. (2015) Ultrasound of the male genital tract in relation to male reproductive health. *Hum Reprod Update* 21, 56–83.
- Madlon-Kay DJ. (1986) Witch's milk. *Am J Dis Child* 140, 252.
- Marshall WA & Tanner JM. (1969) Variations in pattern of pubertal changes in girls. *Arch Dis Child* 44, 291–303.
- Maruyama Y, Adachi Y, Aoki N, Suzuki Y, Shinohara H & Yamamoto T. (1991) Mechanism of feminization in male patients with non-alcoholic liver cirrhosis: role of sex hormone-binding globulin. *Gastroenterol Jpn* 26, 435–439.
- Mathur R & Braunstein GD. (1997) Gynecomastia: pathomechanisms and treatment strategies. *Horm Res* 48, 95–102.
- Matsumoto A & Bremner W. (2011) Male Hypogonadism. In: *Williams Textbook of Endocrinology*, 12th edn (eds S Melmed, K Polonsky, P Larsen & H Kronenberg), pp. 709–755. Saunders, Philadelphia.
- Mauras N, Bishop K, Merinbaum D, Emeribe U, Agbo F & Lowe E. (2009) Pharmacokinetics and pharmacodynamics of anastrozole in pubertal boys with recent-onset gynecomastia. *J Clin Endocrinol Metab* 94, 2975–2978.
- McDermott MT, Hofeldt FD & Kidd GS. (1990) Tamoxifen therapy for painful idiopathic gynecomastia. *South Med J* 83, 1283–1285.
- McKiernan JF & Hull D. (1981) Breast development in the newborn. *Arch Dis Child* 56, 525–529.
- Mendelson JH, Kuehnle J, Ellingboe J & Babor TF. (1974) Plasma testosterone levels before, during and after chronic marihuana smoking. *N Engl J Med* 291, 1051–1055.
- Mieritz MG, Rakét LL, Hagen CP, Nielsen JE, Talman M-LM, Petersen JH, Sommer SH, Main KM, Jørgensen N & Juul A. (2015) A longitudinal study of growth, sex steroids, and IGF-1 in boys with physiological gynecomastia. *J Clin Endocrinol Metab* 100, 3752–3759.
- Mieritz MG, Christiansen P, Jensen MB, Joensen UN, Nordkap L, Olesen IA, Bang AK, Juul A & Jørgensen N. (2017) Gynaecomastia in 786 adult men: clinical and biochemical findings. *Eur J Endocrinol* 176, 555–566.
- Moore DC, Schlaepfer LV, Paunier L & Sizonenko PC. (1984) Hormonal changes during puberty: V. transient pubertal gynecomastia: abnormal androgen-estrogen ratios. *J Clin Endocrinol Metab* 58, 492–499.
- Morales A, Collier CP & Clark AF. (2012) A critical appraisal of accuracy and cost of laboratory methodologies for the diagnosis of hypogonadism: the role of free testosterone assays. *Can J Urol* 19, 6314–6318.
- Muñoz Carrasco R, Alvarez Benito M, Muñoz Gomariz E, Raya Povedano JL & Martínez PM. (2010) Mammography and ultrasound in the evaluation of male breast disease. *Eur Radiol* 20, 2797–2805.
- Nachtigall C. (1965) Progress observations on physiological swelling of the breast in newborn infants. *Monatsschr Kinderheilkd* 113, 497–498.
- Narula HS & Carlson HE. (2014) Gynaecomastia—pathophysiology, diagnosis and treatment. *Nat Rev Endocrinol* 10, 684–698.
- Nichols CR, Heerema NA, Palmer C, Loehrer PJ, Williams SD & Einhorn LH. (1987) Klinefelter's syndrome associated with mediastinal germ cell neoplasms. *J Clin Oncol* 5, 1290–1294.
- Nicolis GL, Modlinger RS & Lester GJ. (1971) A study of the histopathology of human gynecomastia. *J Clin Endocrinol Metab* 32, 173–178.
- Nieschlag E & Vorona E. (2015) Mechanisms in Endocrinology: medical consequences of doping with anabolic androgenic steroids: effects on reproductive functions. *Eur J Endocrinol* 173, R47–R58.
- Niewoehner CB & Nuttall FQ. (1984) Gynecomastia in a hospitalized male population. *Am J Med* 77, 633–638.
- Nuttall F. (1979) Gynecomastia as a physical finding in normal men. *J Clin Endocrinol Metab* 48, 338–340.
- Nuttall F, Warrier R & Gannon M. (2015) Gynecomastia and drugs: a critical evaluation of the literature. *Eur J Clin Pharmacol* 71, 569–578.
- Nydic M, Bustos J, Dale JH & Rawson RW. (1961) Gynecomastia in adolescent boys. *JAMA* 178, 449–454.
- Olivo J, Gordon GG, Rafii F & Southren AL. (1975) Estrogen metabolism in hyperthyroidism and in cirrhosis of the liver. *Steroids* 26, 47–56.
- Olusi SO. (1980) Hyperprolactinaemia in patients with suspected cannabis-induced gynaecomastia. *Lancet* 1, 255.
- Ordaz DL & Thompson JK. (2015) Gynecomastia and psychological functioning: a review of the literature. *Body Image* 15, 141–148.
- Paris F, Gaspari L, Mbou F, Philibert P, Audran F, Morel Y, BIASON-Laubert A & Sultan C. (2016) Endocrine and molecular investigations in a cohort of 25 adolescent males with prominent/persistent pubertal gynecomastia. *Andrology* 4, 263–269.
- Perdonà S, Autorino R, De Placido S, D'Armiento M, Gallo A, Damiano R, Pingitore D, Gallo L, De Sio M, Bianco AR & Di Lorenzo G. (2005) Efficacy of tamoxifen and radiotherapy for prevention and treatment

- of gynaecomastia and breast pain caused by bicalutamide in prostate cancer: a randomised controlled trial. *Lancet Oncol* 6, 295–300.
- Plourde PV, Reiter EO, Jou HC, Desrochers PE, Rubin SD, Bercu BB, Diamond FB & Backeljauw PF. (2004) Safety and efficacy of anastrozole for the treatment of pubertal gynaecomastia: a randomized, double-blind, placebo-controlled trial. *J Clin Endocrinol Metab* 89, 4428–4433.
- Priskorn L, Nordkap L, Bang AK, Krause M, Holmboe SA, Egeberg Palme DL, Winge SB, Mørup N, Carlsen E, Joensen UN, Blomberg Jensen M, Main KM, Juul A, Skakkebaek NE, Jensen TK & Jørgensen N. (2018) Average sperm count remains unchanged despite reduction in maternal smoking: results from a large cross-sectional study with annual investigations over 21 years. *Hum Reprod* 33, 998–1008.
- Quigley CA, De BA, Marschke KB, el-Awady MK, Wilson EM & French FS. (1995) Androgen receptor defects: historical, clinical, and molecular perspectives. *Endocr Rev* 16, 271–321.
- Rahmani S, Turton P, Shaaban A & Dall B. (2011) Overview of gynaecomastia in the modern era and the Leeds gynaecomastia investigation algorithm. *Breast J* 17, 246–255.
- Rew L, Young C, Harrison T & Caridi R. (2015) A systematic review of literature on psychosocial aspects of gynaecomastia in adolescents and young men. *J Adolesc* 43, 206–212.
- Riepe FG, Baus I, Wiest S, Krone N, Sippell WG & Partsch C-J. (2004) Treatment of pubertal gynaecomastia with the specific aromatase inhibitor anastrozole. *Horm Res Paediatr* 62, 113–118.
- Rochefort H & Garcia M. (1983) The estrogenic and antiestrogenic activities of androgens in female target tissues. *Pharmacol Ther* 23, 193–216.
- Sarkar A, Bain J, Bhattacharya D, Sawarappa R, Munian K, Dutta G, Naiyer GJ & Ahmad S. (2014) Role of combined circumareolar skin excision and liposuction in management of high grade gynaecomastia. *J Cutan Aesthet Surg* 7, 112–116.
- Sasano H, Kimura M, Shizawa S, Kimura N & Nagura H. (1996) Aromatase and steroid receptors in gynaecomastia and male breast carcinoma: an immunohistochemical study. *J Clin Endocrinol Metab* 81, 3063–3067.
- Sattin RW, Roisin A, Kafrissen ME, Dugan JB & Farer LS. (1984) Epidemic of gynaecomastia among illegal Haitian entrants. *Public Health Rep* 99, 504–510.
- Schmidt IM. (2002) Gender difference in breast tissue size in infancy: correlation with serum estradiol. *Pediatr Res* 52, 682–686.
- Schonfeld WA. (1962) Gynecomastia in adolescence: effect on body image and personality adaptation. *Psychosom Med* 24, 379–389.
- Smith SR, Chhetri MK, Johanson AJ, Radfar N & Migeon CJ. (1975) The pituitary-gonadal axis in men with protein-calorie malnutrition. *J Clin Endocrinol Metab* 41, 60–69.
- Stratakis CA, Vottero A, Brodie A, Kirschner LS, DeAtkine D, Lu Q, Yue W, Mitsiades CS, Flor AW & Chrousos GP. (1998) The aromatase excess syndrome is associated with feminization of both sexes and autosomal dominant transmission of aberrant P450 aromatase gene transcription. *J Clin Endocrinol Metab* 83, 1348–1357.
- Swiglo BA, Murad MH, Schünemann HJ, Kunz R, Vigersky RA, Guyatt GH & Montori VM. (2008) A case for clarity, consistency, and helpfulness: state-of-the-art clinical practice guidelines in endocrinology using the grading of recommendations, assessment, development, and evaluation system. *J Clin Endocrinol Metab* 93, 666–673.
- Tinggaard J, Mieritz M, Sørensen K, Mouritsen A, Hagen CP, Aksglaede L, Wohlfahrt-Veje C & Juul A. (2012) The physiology and timing of male puberty. *Curr Opin Endocrinol Diabetes Obes* 19, 197–203.
- Volpe CM, Raffetto JD, Collure DW, Hoover EL & Doerr RJ. (1999) Unilateral male breast masses: cancer risk and their evaluation and management. *Am Surg* 65, 250–253.
- Webster MH. (1980) Plastic surgery of the breast. *Practitioner* 224, 406–408.
- Williams MJ. (1963) Gynecomastia. Its incidence, recognition and host characterization in 447 autopsy cases. *Am J Med* 34, 103–112.
- Wu FC, Farley TM, Peregoudov A & Waites GM. (1996) Effects of testosterone enanthate in normal men: experience from a multicenter contraceptive efficacy study. World Health Organization Task Force on Methods for the Regulation of Male Fertility. *Fertil Steril* 65, 626–636.
- Wu FC, Tajar A, Beynon JM, Pye SR, Silman AJ, Finn JD & EMAS Group. (2010) Identification of late-onset hypogonadism in middle-aged and elderly men. *N Engl J Med* 363, 123–135.
- Yu X-F, Yang H-J, Yu Y, Zou D-H & Miao L-L. (2015) A prognostic analysis of male breast cancer (MBC) compared with post-menopausal female breast cancer (FBC). *PLoS ONE* 10, e0136670.