

# Current trends and therapies in orchialgia management

Kevin Campbell  and Larry Lipshultz

*Ther Adv Urol*

2021, Vol. 13: 1–8

DOI: 10.1177/  
17562872211026433

© The Author(s), 2021.  
Article reuse guidelines:  
sagepub.com/journals-  
permissions

**Abstract:** The management of pain is a complex condition that will be encountered by most practicing clinicians. In the genitourinary community, testicular pain may be classified as acute or chronic. Initial evaluation of chronic groin and scrotal content pain (CGSCP) begins with a detailed history and physical examination to elucidate the presenting pathology. Multiple therapy algorithms have been proposed with no definitive consensus; however, most begin with conservative intervention and medical management prior to advancing to more invasive procedures. Surgical approaches may range from reconstruction, as in vasovasostomy for post-vasectomy pain syndrome, to excision of the offending agent, as in epididymectomy. This review seeks to focus on chronic pain in the genitourinary community and review techniques of pain management in the current intervention for orchialgia, as well as identify future methods of treatment.

**Keywords:** orchialgia, testalgia, scrotal pain, testicular pain, chronic pain

Received: 18 January 2021; revised manuscript accepted: 1 June 2021.

## Introduction

Orchialgia is a condition that has plagued the waiting rooms of clinicians from family practitioners, urologists, to internists. This review seeks to focus on chronic pain in the genitourinary community and review techniques of pain management in the current intervention for orchialgia, as well as identify future methods of treatment.

## History of pain management

The management of pain in the Western world begins fundamentally with the prescription of opium in the 1600s. In the 1800s, ether and chloroform were introduced as anesthetics for surgery and with them brought the ethical concerns for operating on an unconscious patient.<sup>1</sup> By the 1900s, morphine and heroin were employed for pain control by physicians. The concept of managing chronic pain then began to gain interest and by the 1960s, pain “control” was recognized as a field of medicine, with the journal *Pain* publishing its first issue in 1975. In the 1980s several pain specialists suggested that opioids were associated with a “low incidence of addictive behavior.” The

next 20 years promulgated the belief among physicians that opioids could be prescribed freely and became a driving factor for the current opioid crisis. Currently, there are over 116 million Americans diagnosed with chronic pain, with drug overdose deaths continuing to increase in the United States.

From 1999 to 2016, more than 630,000 Americans have died from a drug overdose.<sup>2</sup> Around 66% of these deaths involved an opioid. In 2016, the number of overdose deaths involving opioids was five times higher than in 1999. On average, 115 Americans die every day from an opioid overdose.

On 26 October 2017, President Trump declared the opioid crisis a national Public Health Emergency under federal law, stating “I am directing all executive agencies to use every appropriate emergency authority to fight the opioid crisis.”

Additionally, the number of high-profile government and class action settlements against opioid companies has increased both in frequency and in

Correspondence to:  
**Kevin Campbell**  
Baylor College of  
Medicine, Suite 1700, 6624  
Fannin, Houston, TX 77030,  
USA  
[Kevin.campbell@bcm.edu](mailto:Kevin.campbell@bcm.edu)  
**Larry Lipshultz**  
Baylor College of  
Medicine, Houston, TX,  
USA

magnitude in recent years.<sup>3</sup> Some of the earliest suits against opioid manufacturers were seen in the early 2000s as personal injury claims brought on behalf of addicts by their families. The suits were based on the belief that the manufacturers deliberately withheld information about their products' dangers and had misrepresented them as being safer than the available alternatives.

In a recent article by Blendon and Benson, data cited reported that public opinion is divided among who bears the responsibility for fighting addiction. Thirty-three percent of those polled blamed doctors for inappropriately prescribing painkillers. Surprisingly, only 28% attributed the blame to illegal transactions involving drug dealers.<sup>4</sup> The authors also noted that two-thirds of the public had been prescribed an opioid for pain, while 7% worried they could become addicted to a prescribed pain medication. Half of those polled admitted to knowing someone addicted to prescription painkillers.

### Orchialgia and the clinician

Chronic pain takes different faces as it manifests itself in the different disciplines of medicine. The general clinician will often encounter orchialgia throughout their practice. Also known as chronic groin or scrotal content pain (CGSCP) or testicular pain syndrome, orchialgia is defined as "intermittent or constant testicular pain that is either unilateral or bilateral and occurs for a duration of more than 3 months." Though there are many treatments aimed at CGSCP, the etiology and pathophysiology of the condition and its natural history are poorly understood. There is no definitive data on the incidence and prevalence, though its prevalence is estimated at 0.4–4.75% in specific groups of men and incidence >100,000 men per year.<sup>4–6</sup> Certain groups of men have a high incidence with 1–15% of vasectomized men having chronic pain following their procedure and up to 3–6% of patients post inguinal hernia repair.<sup>5</sup> It is estimated that 2.5% of all urology visits can be attributed to CGSCP.

Patients who present with this condition have already seen a mean of 4.5 physicians and undergo an average of 7.2 diagnostic interventions in an attempt to find a solution for their pain.<sup>6</sup> Treatment can become frustrating in that up to 50% of patients will have no identifiable etiology for their pain despite an exhaustive diagnostic trail.<sup>7,8</sup>

Testicular pain can be divided into two very broad categories: acute or chronic. Acute pain may be attributed to trauma, torsion of the testicle or appendage, epididymitis, venous thrombosis, a strangulated hernia, nephrolithiasis, or even appendicitis.<sup>9</sup> On the other hand the development of chronic pain is often more complex, frequently with confounding factors. Causative factors may include a hydrocele, spermatocele, tumor, infection, varicocele, post-vasectomy pain, referred pain (radiculitis, multiple neuropathies), autoimmune as in IgG4 perivascular fibrosis, and idiopathic.<sup>10</sup>

Herein, we review common causes of orchialgia and treatments compiled from a *PubMed* review of "orchialgia" and "scrotal pain." Treatment options presented have demonstrated prominence through multiple search options or clinical or basic science research.

### Initial evaluation

Evaluation and workup of CGSCP begins with a detailed history including prior scrotal, inguinal, or abdominopelvic surgeries. Previous psychological, physical, or sexual abuse should be documented with direct questioning about depression and self-harm. Note whether the patient has the presence of other pain conditions such as fibromyalgia or chronic pain/chronic pelvic pain syndrome and the impact of CGSCP on the patient's life, that is, sexual, urinary, and bowel function involvement. There are currently few clinically validated questionnaires specifically for CGSCP. Polackwich *et al.*<sup>11</sup> developed a new validated chronic orchialgia symptom index, the chronic orchialgia symptom index, based on a score of 0–37, to improve the assessment and study of patients.<sup>12</sup> Additionally, there is a Chronic Epididymitis Symptom Index, adapted from the National Institutes of Health Chronic Prostatitis Symptom Index questionnaire.<sup>13</sup>

The physical exam should be performed standing as well as supine, including the identification of scars (abdominal, inguinal, or scrotal) or the presence of a hernia. The scrotum is evaluated first on the non-tender side, assessing for testicular size and consistency, testicular masses, epididymal abnormalities, or clinically apparent varicoceles. A digital rectal exam evaluates for prostatic tenderness and hypertonicity/tenderness of pelvic floor musculature.

Workup may also include a urinalysis and infection screen for sexually transmitted infections (e.g. *Chlamydia trachomatis*, *Neisseria gonorrhoeae*) with treatment if positive.

Most patients with CGSSCP will have gone through imaging at some point in their evaluation. Van Haarst *et al.*<sup>14</sup> performed a review involving the findings of 111 patients with scrotal pain lasting longer than 2 weeks with unremarkable physical examinations and urinalyses who underwent an ultrasound evaluation. They noted that the scrotal ultrasound was normal in 77 patients, with 12 patients showing a minimal amount of fluid, interpreted by the radiologist as physiologic. Three of the patients had larger fluid collections which had already been diagnosed on physical exam as hydroceles. All 15 of the patients with fluid collections had normal scrotal contents, additionally with no correlation between the presence of the fluid and pain location. The investigators noted that although there is little harm, other than economic reasons and its burden on radiologic services, to use a simple and fast modality such as ultrasound, its main indication seems to be to reassure the patient and his doctor that no serious pathologic features are present. They also stated that “Doctors should learn again to put their trust in their abilities to perform a physical examination of the scrotum.”

### Pathophysiology

As previously stated, CGSCP pathophysiology is not well understood. The proposed central concept of etiology involves central sensitization where a peripheral injury triggers a long-lasting increase in the excitability of spinal neurons.<sup>15</sup> Shiraishi and Matsuyama<sup>15</sup> elucidated the surgical anatomy of the spermatic cords in relation to the micro nerves and lymphatics in the human spermatic fascia. They noted a high density of sensory and sympathetic nerve fibers in the spermatic cord, particularly around the vas deferens. The nerves in the spermatic fascia may be related to orchialgia. Nerve ligation in these areas during surgical intervention may explain the success of the procedure in eliminating pain in these areas and suggest that perhaps targeted ligation may provide sufficient pain relief.

The two hit theory of Wallerian degeneration of testicular nerves includes a baseline inflammatory or genetic process with subsequent hypersensitivity of the ilioinguinal and genitofemoral nerves.<sup>7</sup>

A second inciting event leads to chronic neuropathy.

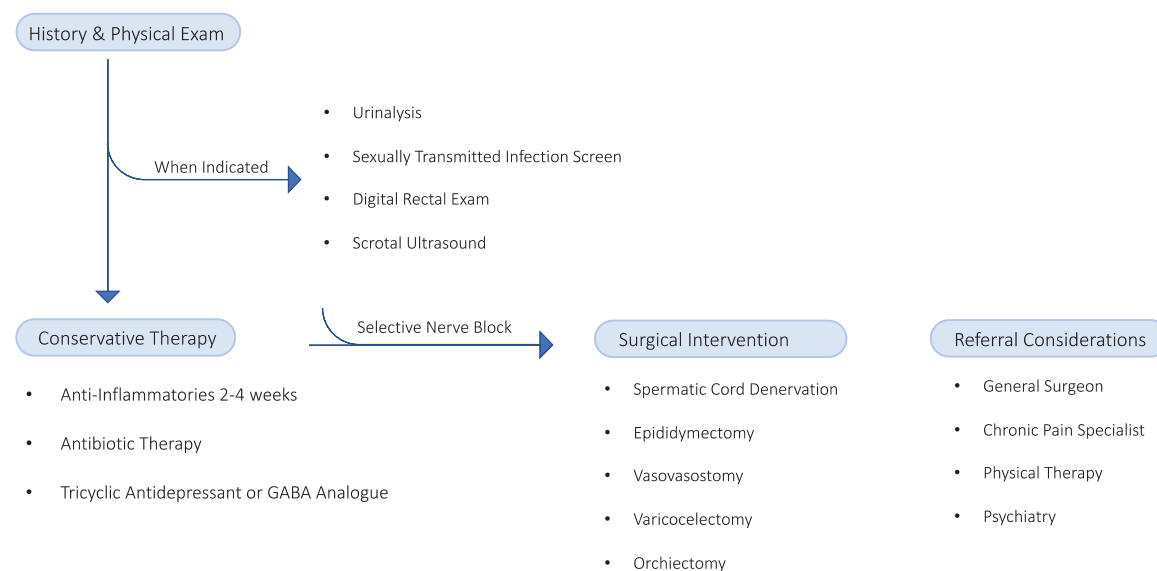
Scrotal afferent innervation originates *via* somatic nerves in the genital branch of the genitofemoral nerve, ilioinguinal nerves, and autonomic branches from T10-L1 parasympathetic ganglia. The genitofemoral (S1, S2) and ilioinguinal nerves (T12, L1) provide anterior scrotal wall and thigh innervation. The posterior scrotal wall is innervated *via* the perineal branches of the pudendal nerve.

There is an alternative autonomic pathway between the pelvic plexus and testis *via* the vas deferens, which explains the positive response to anesthetic injections to the pelvic ganglia. This occurs *via* somatic nerves in the genital branch of the genitofemoral nerve and the ilioinguinal nerve, as well as autonomic branches from the parasympathetic ganglia of T10-L1 for the epididymis and vas deferens. It should be noted that there is significant crossover and overlap of sensory input occurs from the ilioinguinal, iliohypogastric, and genitofemoral nerves. Any organ that shares the same nerve pathway with the scrotal contents can present with referred pain in this region, such as the ureter and hip.

### Initial therapy

Initial therapy algorithms have been proposed with no definitive consensus; however, most begin with conservative intervention including watchful waiting with scrotal suspension, non-steroidal anti-inflammatory drugs, antibiotics, and antidepressants (Figure 1).<sup>16</sup> Medical management may begin with anti-inflammatories for >2–4 weeks. Focal tenderness of the epididymis or prostate should be managed with empiric antibiotic therapy for 2–4 weeks. If neuropathic pain is suspected, a tricyclic antidepressant, gabapentin, or pregabalin may be trialed for 4–6 weeks.

If conservative therapy fails, the patient is often referred to a urologist for surgical or procedural therapy. A spermatic cord block may be performed for diagnostic and therapeutic effect. If the spermatic cord block resolves the pain by at least 50%, denervation of the spermatic cord may be pursued.<sup>8,9</sup> If the block does not resolve the pain, the diagnosis should be reevaluated with a more detailed history and possible labs and imaging. Options for failure of denervation of the spermatic cord include spermatic cord



**Figure 1.** Initial workup and treatment algorithm for orchialgia.  
GABA, gamma-aminobutyric acid.

microcrosablation, onabotulinum toxin injections, and, last, salvage orchiectomy.

A clinically significant varicocele should be referred for varicocele repair. Epididymectomy is also a reported surgical procedure for CGSCP with a variable success rate ranging from a durable response from 10% to >90%.<sup>13</sup>

### Selective nerve block

The spermatic nerve block has the benefit of diagnostic and therapeutic yield. It is often performed at the pubic tubercle, 1 cm inferior and 1 cm medial. The block targets the high nerve density within and around the spermatic cord. The genitofemoral nerve lies immediately lateral to the spermatic cord, external to the superficial inguinal ring. The analgesia is performed with a selection or combination of lidocaine 1–2% and 0.25% bupivacaine, blocking fast voltage-gated Na-channels essential for neuronal transmission.<sup>17</sup> Lidocaine maintains a duration of action for 2 h and bupivacaine for 4–8 h. The blocks may be repeated every 3–4 weeks for a durable response if the patient is hesitant to proceed with surgical intervention.

### Epididymectomy

Epididymectomy has been shown to be an effective treatment option with excellent long-term symptomatic outcomes and high rates of patient

satisfaction for chronic pain localized to the epididymis. Key to patient satisfaction and success are careful patient selection and counseling. Epididymectomy is an option for the relief of epididymal pain related to postoperative obstruction, epididymal cysts, or epididymitis. Siu *et al.* performed 66 epididymectomies on 52 patients from 1996 to 2006 for localized epididymal pain.<sup>18</sup> At an average follow-up of 45.8 months, 70% of patients reported no pain following epididymectomy. Of the patients still with pain, 62 reported less pain. Overall 90% were very satisfied or satisfied with their choice to undergo the procedure. In a separate study, Hori *et al.* evaluated 53 patients who underwent epididymectomy between 1994 and 2007 for a mean follow-up of 7.4 years.<sup>19</sup> At 85%, the majority of patients underwent epididymectomy for post-vasectomy pain and the remainder had the procedure for various non-vasectomy reasons. There were significant improvements in pain scores in the post-vasectomy group, with 93.3% with less or no postoperative pain compared with 75% in the non-vasectomy group.

### Varicocelectomy

Subinguinal as well as laparoscopic varicocelectomies have been employed in the management of chronic inguinal pain attributed to varicoceles.<sup>20</sup> Kachrilas *et al.* noted over 90% of patients reporting relief of pain following laparoscopic varicocelectomy in patients with unilateral or bilateral

varicoceles. Their cohort included 48 patients with dull scrotal pain attributable to varicoceles.<sup>21</sup> Eighty-seven percent of patients noted significant improvement on a visual analog scale score, 10% reported some symptom improvement, and 2% remained unchanged. Interestingly 10% of patients developed a recurrence and 8% of patients developed a *de novo* hydrocele.

### Orchiectomy

Orchiectomy is reserved for failure to respond to conservative and invasive methods. It is not a favorable primary option as it holds the potential for phantom pain. Initial pain reduction was quoted as between 40% and 75%; however, this is based on Finnish audits by Rönkä *et al.* which evaluated a cohort of patients with orchialgia following inguinal hernia surgery.<sup>22</sup> The inguinal approach appears to have higher rates of pain resolution over a scrotal approach.

### Microsurgical denervation of the spermatic cord

Microsurgical denervation of the spermatic cord (MSDSC) offers a testis-sparing intervention that reduces physical and psychological morbidity. It has reported response rates of from 52% to 100%.<sup>7,8,10,16,23</sup> Multiple techniques have been described, with two main approaches: an inguinal and a subinguinal approach. The inguinal approach was first described by Devine and Schellhammer in 1978 and offers the surgeon the ability to bury the proximal segment of the ilioinguinal nerve after being severed, which may reduce the risk of neuroma formation.<sup>23</sup> The subinguinal approach may be more comfortable for some surgeons as this is similar to that for microscopic varicocelectomy.<sup>5</sup> The subinguinal approach is also non-muscle splitting and has become the modality of choice in this operation.<sup>16,24–26</sup> A 2-cm incision is performed inguinally or subinguinally and the spermatic cord is mobilized with its fascial layers. The ilioinguinal nerve is identified and divided. Operative magnification is used to assist in opening the fascial layers of the spermatic cord, which are then separated and divided with clips or silk ligatures. The arterial branches are identified by Doppler ultrasound and preserved, as are veins and lymphatics. The vas deferens is divided if the patient previously underwent a vasectomy. The cord is then placed back into the incision and deep tissue and skin are closed.

The success of denervation of the cord is postulated to be attributed to ablation of the hypersensitive afferent nerve pathways in the cremasteric musculature, perivascular fascia, periarterial tissue, and surrounding pericord lipomatous tissues. Parekattil *et al.* retrospectively reviewed spermatic cord biopsies of 56 patients with CGSCP who underwent MSDSC.<sup>27</sup> They noted that there appeared to be Wallerian degeneration in reproducible patterns in the spermatic cord nerve fibers when compared with controls in patients undergoing orchiectomy and varicocelectomy. The degeneration was noted at three primary sites, including the cremasteric muscle, perivascularly, and in the peri-arterial/lipomatous tissue.

These findings may be considered for more of a targeted MSDSC in which the spermatic cord is isolated, the cremaster is divided circumferentially, and the posterior lipomatous and perivessel tissues are fulgurated with electrocautery. The perivessel tissues and vasal sheath are ligated under microsurgical visualization. The traditional and targeted denervation were compared in a retrospective review by Kavoussi with 39 patients receiving a full MSDSC and 43 receiving a targeted MSDSC. Follow-up was maintained for up to a year with similar outcomes and targeted MSDSC having a significantly decreased operative time (53 min *versus* 21 min).<sup>28</sup>

MSDSC has been explored prospectively in a 2015 multicenter study by Marconi *et al.* which enrolled 50 patients with >3 month duration CGSCP and a positive response to spermatic cord block.<sup>29</sup> They reviewed 52 testicular units denervated with a subinguinal approach. There were no noted intraoperative complications. Two patients required reoperations for a hematocele and hydrocele. At 6 months after surgery 80% of patients were pain free. Twelve percent of patients had intermittent testicular discomfort with relief from on demand acetaminophen, and 8% of patients had no change in their pain.

Microsurgical denervation of the spermatic cord has also been targeted from a robotic approach. Calixte *et al.* performed a retrospective review of 772 patients who underwent a targeted robotic-assisted microsurgical denervation of the cord for testicular pain of greater than 3 months' duration that had failed conservative treatment.<sup>30</sup> They assessed pain using the PIQ-6 questionnaire preoperatively and postoperatively with a median follow-up of 24 months. Findings demonstrated a



significant reduction in pain in 67% of patients 6 months postoperatively, 77% at 2 years, and 86% at 3 years.

### Post-vasectomy pain

Post-vasectomy pain syndrome is a rare but present complication of vasectomies. It is characterized by prolonged scrotal pain following acute post-procedural pain, usually greater than 2–4 weeks.<sup>31,32</sup> The pain can be associated with intercourse, ejaculation, or physical exertion. The pathophysiology is unclear but thought to be due to congestion causing back pressure as a result of the vas and epididymis trapped between two opposing forces during ejaculation. The immune response results in an inflammatory effect on the scrotal and spermatic cord nerve structures. Perineural fibrosis develops from fluid discharged into the caudal epididymis, increasing the back pressure and leading to pain. MSDSC may be offered to these patients if they fail to improve with conservative therapies.

### Other therapies

#### Multiphoton microscopy

Multiphoton microscopy uses laser ablation to create cavitation bubbles and selective damage to targeted tissue. Identification of spermatic cord nerves is not feasible with an OR microscope or robotic stereoscope. To this effect, Ramasamy *et al.* identified and ablated nerves *in vivo* in a rat model using multiphoton microscopy.<sup>33</sup> They identified nerve fiber bundles in each spermatic cord and, under the same magnification, performed high-power laser ablation of the nerves. Precise ablation of nerves and preservation of surrounding structures was confirmed by histological analysis.

#### Ultrasound-guided targeted cryoablation of the perispermatic cord

Ultrasound-guided targeted cryoablation (UTC) of the perispermatic cord has been suggested for persistent chronic scrotal content pain following microsurgical denervation of the spermatic cord.<sup>34</sup> Calixte *et al.* retrospectively evaluated 279 cases of patients with persistent pain following microsurgical denervation of the spermatic cord. These patients demonstrated transient pain relief after a spermatic cord block and were offered UTC. A 1.7 mm cryoprobe was placed medial and lateral

to the spermatic cord at the level of the external ring to target nerve branches of the ilioinguinal, genitofemoral, and inferior hypogastric nerves. Argon gas was used to perform two freeze cycles, creating a 1.5 cm ice ball, with an interval passive thaw cycle. They followed patients for 36 months postoperatively and found a 75% significant reduction in pain. Moreover, 11% demonstrated complete resolution and 64% had >50% reduction in pain.

#### Pulsed radiofrequency

Pulsed radiofrequency (PRF) applies a relatively high voltage near a nerve to create an electric field without injury to the nerve rather than thermally-induced changes. Previous reports of patients have demonstrated successful treatment of orchialgia with PRF. Basal *et al.* used a 22-gauge, 5 cm cannula inserted into the spermatic cord 2 cm from the external inguinal ring with a 10 mm active tip to administer 45 V for a duration of 3 min to treat chronic orchialgia in five patients.<sup>35</sup> They had temporary pain relief after undergoing outpatient diagnostic cord block. Though this is a limited case report on short-term use of RPF, no recurrence of pain was noted on visual analog scores at a mean follow-up of 20 weeks.

#### Onabotulinum toxin

Onabotulinum toxin A has been shown to modulate the release of neuropeptides substance P and calcitonin with inhibition of neurogenic inflammation and chronic pain. A total of 100 U of onabotulinum toxin A is diluted in 10 cc of saline and injected medial and lateral to the spermatic cord at the external inguinal ring. Results of a recent randomized, double-blind, controlled trial have demonstrated that nerve blocks performed with onabotulinum toxin A showed no superiority when compared with local anesthesia alone for the control of chronic scrotal pain.<sup>36</sup>

### Conclusions

Chronic orchialgia is a complex condition that will be encountered by most practicing clinicians. When should a surgeon operate for scrotal pain? The short answer is that one should operate only when one has to. The goal is to operate less and on better selected patients with more focused procedures. Testicular pain treatment should follow a systematic protocol that may be escalated to surgery when conservative therapy fails. Referral

to adjunct specialties such as a chronic pain specialist, psychiatrist, physical therapist, or general surgeon may also be indicated.

### Conflict of interest statement

The author(s) declare that there is no conflict of interest.

### Funding

The author(s) received no financial support for the research, authorship, and/or publication of this article.

### ORCID iD

Kevin Campbell  <https://orcid.org/0000-0002-2594-2219>

### References

- Collier R. A short history of pain management. *CMAJ* 2018; 190: E26–E27.
- Centers for Disease Control and Prevention. Opioid data analysis and resources. Drug Overdose. CDC Injury Center, <https://www.cdc.gov/drugoverdose/data/analysis.html> (2018, accessed 12 October 2019).
- Haffajee RL and Mello MM. Drug companies' liability for the opioid epidemic. *N Engl J Med* 2017; 377: 2301–2305.
- Blendon RJ and Benson JM. The public and the opioid-abuse epidemic. *N Engl J Med* 2018; 378: 407–411.
- Davis BE, Noble MJ, Weigel JW, *et al.* Analysis and management of chronic testicular pain. *J Urol* 1990; 143: 936–939.
- Ciftci H, Savas M, Yeni E, *et al.* Chronic orchialgia and associated diseases. *Curr Urol* 2010; 4: 67–70.
- Calixte N, Brahmabhatt J and Parekattil S. Chronic testicular and groin pain: pathway to relief. *Curr Urol Rep* 2017; 18: 83.
- Levine LA and Hoch MP. Evaluation and management of chronic scrotal content pain. *Curr Urol Rep* 2015; 16: 36.
- Wu C and Jarvi K. Management of chronic scrotal content pain. *Can Urol Assoc J* 2018; 12(6 Suppl. 3): S164–S166.
- Heidenreich A, Olbert P and Engelmann UH. Management of chronic testalgia by microsurgical testicular denervation. *Eur Urol* 2002; 41: 392–397.
- Polackwich AS, Arora HC, Li J, *et al.* Development of a clinically relevant symptom index to assess patients with chronic orchialgia/chronic scrotal content pain. *Transl Androl Urol* 2018; 7(Suppl. 2): S163–S168.
- Shoskes DA, Calixte N, Tadros N, *et al.* Validation of the chronic orchialgia symptom index for men with chronic orchialgia/chronic scrotal contents pain. *Urology* 2018; 119: 39–43.
- Nickel JC, Siemens DR, Nickel KR, *et al.* The patient with chronic epididymitis: characterization of an enigmatic syndrome. *J Urol* 2002; 167: 1701–1704.
- Van Haarst EP, van Andel G, Rijcken TH, *et al.* Value of diagnostic ultrasound in patients with chronic scrotal pain and normal findings on clinical examination. *Urology* 1999; 54: 1068–1072.
- Oka S, Shiraishi K and Matsuyama H. Microsurgical anatomy of the spermatic cord and spermatic fascia: distribution of lymphatics, and sensory and autonomic nerves. *J Urol* 2016; 195: 1841–1847.
- Tatem A and Kovac JR. Chronic scrotal pain and microsurgical spermatic cord denervation: tricks of the trade. *Transl Androl Urol* 2017; 6(Suppl. 1): S30–S36.
- Gordon J and Rifenburg RP. Spermatic cord anesthesia block: an old technique re-imaged. *West J Emerg Med* 2016; 17: 811–813.
- Siu W, Ohl DA and Schuster TG. Long-term follow-up after epididymectomy for chronic epididymal pain. *Urology* 2007; 70: 333–335.
- Hori S, Sengupta A, Shukla CJ, *et al.* Long-term outcome of epididymectomy for the management of chronic epididymal pain. *J Urol* 2009; 182: 1407–12. Epub ahead of print 15 August 2009. DOI: 10.1016/j.uro.2009.06.020.
- Yaman O, Ozdiler E, Anafarta K, *et al.* Effect of microsurgical subinguinal varicocele ligation to treat pain. *Urology* 2000; 55: 107–108.
- Kachrilas S, Popov E, Bourdounis A, *et al.* Laparoscopic varicolectomy in the management of chronic scrotal pain. *JSL* 2014; 18: e2014.00302.
- Rönkä K, Vironen J, Kokki H, *et al.* Role of orchiectomy in severe testicular pain after inguinal hernia surgery: audit of the Finnish Patient Insurance Centre. *Hernia* 2015; 19: 53–59.
- Devine CJ Jr and Schellhammer PF. The use of microsurgical denervation of the spermatic cord for orchialgia. *Trans Am Assoc Genitourin Surg* 1978; 70: 149–151.

24. Oomen JAR, Witjens AC, van Wijck AJM, *et al.* Prospective double-blind preoperative pain clinic screening before microsurgical denervation of the spermatic cord in patients with testicular pain syndrome. *Pain* 2014; 155: 1720–1726.
25. Cassidy DJ. Early experience with microsurgical spermatic cord denervation for chronic orchialgia at a Canadian centre. *Can Urol Assoc J* 2015; 9: e72–e74.
26. Strom KH and Levine LA. Microsurgical denervation of the spermatic cord for chronic orchialgia: long-term results from a single center. *J Urol* 2008; 180: 949–953.
27. Parekattil SJ, Gudeloglu A, Brahmabhatt JV, *et al.* Trifecta nerve complex: potential anatomical basis for microsurgical denervation of the spermatic cord for chronic orchialgia. *J Urol* 2013; 190: 265–270.
28. Kavoussi PK. Validation of targeted microsurgical spermatic cord denervation: comparison of outcomes to traditional complete microsurgical spermatic cord denervation. *Asian J Androl* 2019; 21: 319–323.
29. Marconi M, Palma C, Troncoso P, *et al.* Microsurgical spermatic cord denervation as a treatment for chronic scrotal content pain: a multicenter open label trial. *J Urol* 2015; 194: 1323–1327.
30. Calixte N, Tojuola B, Kartal I, *et al.* Targeted robotic assisted microsurgical denervation of the spermatic cord for the treatment of chronic orchialgia or groin pain: a single center, large series review. *J Urol* 2018; 199: 1015–1022.
31. Christiansen CG and Sandlow JJ. Testicular pain following vasectomy: a review of postvasectomy pain syndrome. *J Androl* 2003; 24: 293–298.
32. Tan WP, Tsambarlis PN and Levine LA. Microdenervation of the spermatic cord for post-vasectomy pain syndrome. *BJU Int* 2018; 121: 667–673.
33. Ramasamy R, Sterling J, Li PS, *et al.* Multiphoton imaging and laser ablation of rodent spermatic cord nerves: potential treatment for patients with chronic orchialgia. *J Urol* 2012; 187: 733–738.
34. Calixte N, Kartal IG, Tojuola B, *et al.* Salvage ultrasound-guided targeted cryoablation of the perispermatic cord for persistent chronic scrotal content pain after microsurgical denervation of the spermatic cord. *Urology* 2019; 130: 181–185.
35. Basal S, Ergin A, Yildirim I, *et al.* A novel treatment of chronic orchialgia. *J Androl* 2012; 33: 22–26.
36. Dockray J, Aljumaily A, Lau S, *et al.* A Randomized, double-blind controlled trial shows that onabotulinum toxin a nerve blocks do not provide improved pain control in men with chronic scrotal pain. *J Urol* 2020; 203: 767–772.